

# Machine Learning for Cataract Classification and Grading on Ophthalmic Imaging Modalities: A Survey

Xiaoqing Zhang, Yan Hu, JianSheng Fang, Zunjie Xiao, Risa Higashita, and Jiang Liu *Senior Member, IEEE*

**Abstract**—Cataracts are the leading causes for vision impairment and blindness globally. Over the years, researchers have achieved significant progress in developing state-of-the-art artificial intelligence techniques for automatic cataract classification and grading, helping clinicians prevent and treat cataract in time. This paper provides a comprehensive survey of recent advances in machine learning for cataract classification and grading based on ophthalmic images. We summarize existing literature from two research directions: conventional machine learning methods and deep learning methods. This paper also provides insights into existing works of both merits and limitations. In addition, we discuss several challenges of automatic cataract classification and grading based on machine learning techniques and present possible solutions to these challenges for future research.

**Index Terms**—Cataract, classification and grading, ophthalmic image, machine learning, deep learning.

## I. INTRODUCTION

ACCORDING to World Health Organization (WHO) [1], [2], it is estimated that approximately 2.2 billion people suffer vision impairment. Cataract accounts for approximately 33% cases of visual impairment and is the number one cause of blindness (over 50%) worldwide. Cataract patients can improve their life quality and vision through early intervention and cataract surgery as well as reduce blindness ratio and cataract-blindness burden for society efficiently.

Clinically, cataracts are the loss of crystalline lens transparency, which occur when the protein inside the lens clumps together [3]. They are associated with many factors, such as developmental abnormalities, trauma, metabolic disorders, genetics, drug-induced changes, and ages, etc [4], where genetics and aging is the most important causes for cataracts. According to the causes of cataracts, they can be categorized as age-related cataract, pediatrics cataract (PC), and secondary cataract [3], [4]. According to the location of the lens opacity, they can be grouped into nuclear cataract (NC), cortical cataract (CC), and posterior subcapsular cataract (PSC) [5], [6]. NC denotes the gradual clouding of the lens's nucleus area and the progressive hardening. CC is the form of white wedged-shaped and radially oriented opacities, and it develops from the outside edge of the lens toward the center in a spoke-like fashion [4], [7]. PSC is granular opacities. Clinically, cataracts are the loss of crystalline lens transparency, which occurs when the protein inside the lens clumps together [3]. They are associated with many factors, such as developmental abnormalities, trauma, metabolic disorders, drug-induced changes, and ages, etc [4]. According to the causes

of cataracts, they can be categorized as age-related cataract, pediatrics cataract, and secondary cataract [3], [4]. According to the location of the lens opacity, they can be grouped into nuclear cataract (NC), cortical cataract (CC), and posterior subcapsular cataract (PSC) [5], [6]. NC denotes the gradual clouding of the lens's nucleus area and the progressive hardening. CC is the form of white wedged-shaped, and radially oriented opacities, which occurs from the outside edge of the lens toward the center in a spoke-like fashion [7], [8]. PSC is granular opacities, and its symptom includes small breadcrumbs or sand particles which sprinkled beneath the lens capsule [6].

Over the past years, ophthalmologists have used several ophthalmic images to diagnose cataract based on gold cataract grading systems [9]. This manual diagnosis mode is error-prone, time-consuming, subjective, and costly, which is a great challenge in developing countries or rural communities, where experienced clinicians are scarce. To prevent cataract early and improve the precision of diagnosis, researchers have made great efforts in developing massive machine learning (ML) methods for automatic cataract classification and grading [10] on different ophthalmic images, e.g., Li et al. [11] studied automatic cataract grading with feature extraction methods and support vector machine regression (SVR) on slit lamp images. [12], [13] uses fundus images for automatic cataract classification.

Previous surveys had summarized cataract types, cataract grading systems, and ophthalmic imaging modalities, respectively [4], [14]–[19], but none of them had summarized ML techniques based on ophthalmic imaging modalities for automatic cataract classification and grading systematically. To the best of our knowledge, this is the first paper that summarizes recent advances in ML techniques of automatic cataract classification and grading systematically. This paper mainly focuses on surveying ML techniques in cataract classification and grading, comprised of conventional ML methods and deep learning methods. We survey these published papers through Web of Science (WoS), Scopus, and Google Scholar databases, and Figure 1 provides a general framework for this survey based on the collected papers, our summary, and discussion with experienced ophthalmologists. To understand this survey easily, we also review ophthalmic imaging modalities, cataract grading systems, and commonly-used evaluation measures in brief. Then we introduce ML techniques step by step. We hope this paper can provide a useful summary of existing works, and present potential research directions of ML-based cataract

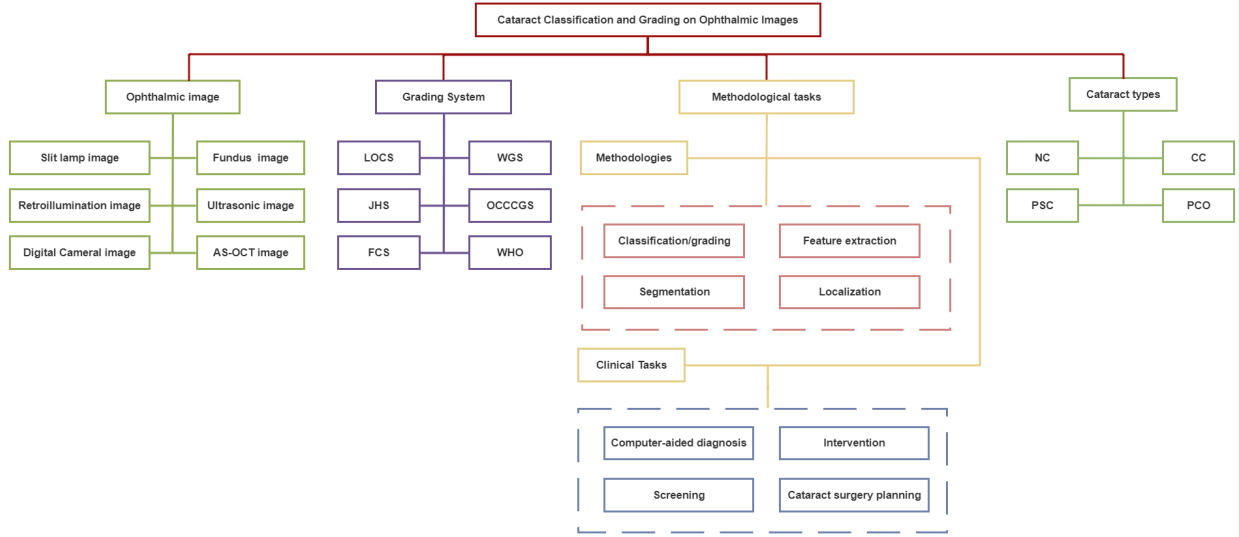


Fig. 1. Illustration of ophthalmic image-based cataract classification and grading analysis.

classification and grading in the future.

## II. OPHTHALMIC IMAGING MODALITIES

This section briefly introduces six ophthalmic images, comprised of slit-lamp images, retroillumination images, ultrasonic images, fundus images, digital camera images, and anterior segment optical coherence tomography (AS-OCT) images.

### A. Slit Lamp Images

The slit lamp camera [20], [21] is a high-intensity light source instrument, which is comprised of the corneal microscope and the slit lamp. Slit lamp image can be accessed through slit lamp camera, which is usually used to examine the anterior segment and posterior segment of the human eye including eyelid, sclera, conjunctiva, iris, crystalline lens, and cornea, etc, as shown in Figure 2.

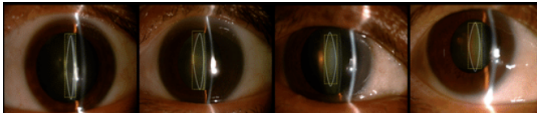


Fig. 2. Slit lamp images.

### B. Retroillumination Images

Retroillumination image is a non-stereoscopic medical image, which is accessed through the crystalline lens camera [22], [23]. It can be used to diagnose CC and PSC in the eye lens. Two types of retroillumination images through the crystalline lens camera can be obtained: an anterior image focused on the iris which corresponds to the anterior cortex of the lens, and a posterior image focused on 3-5mm more posteriorly which intends to image the opacity of PSC.

### C. Ultrasonic Images

In clinical diagnosis, Ultrasound images are an efficient method to evaluate the hardness of the cataract lenses objectively [24]. Frequently applied Ultrasound imaging techniques usually are developed based on measuring ultrasonic attenuation and sound speed, which may increase the hardness of the cataract lens [25]. High-frequency Ultrasound B-mode imaging can be used to monitor local cataract formation, but it cannot measure the lens hardness accurately [26]. To make up for the B-scan deficiency, the Ultrasound imaging technique built on Nakagami statistical model called Ultrasonic Nakagami imaging [27]–[29] was developed and can be used for the visualization of local scatterer concentrations in biological tissues.

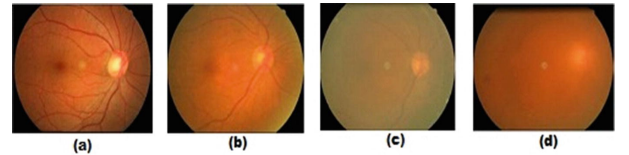


Fig. 3. Four cataract severity levels on fundus images [30]. (a) Normal; (b) Immature; (c) Mature; (d) Hypermature

### D. Fundus Images

The fundus camera [31], [32] is a unique camera in conjunction with a low power microscope, which is usually used to capture fundus images operated by ophthalmologists or professional operators. Fundus image is a highly specialized form of eye imaging and can capture the eye's inner lining and the structures of the back of the eye. Figure 3 shows the fundus images of four different cataract severity levels.

### E. Digital Camera Images

Common digital cameras can access digital camera images like smart phone camera. Compared with the fundus camera

and slit lamp device, the digital camera is easily-available and easy-use equipment. Using digital cameras for cataract screening has great potential in the future, especially for developing countries and areas, where have limitation to access ocular medical equipment and experienced ophthalmologists.

#### F. Anterior Segment Optical Coherence Tomography Images

Anterior segment optical coherence tomography (AS-OCT) [33] imaging technique is one type of optical coherence tomography (OCT) imaging techniques. It can be used to visualize and assess anterior segment ocular features, such as the tear film, cornea, conjunctiva, sclera, rectus muscles, anterior chamber angle structures, and lens [34]–[37]. AS-OCT image can provide high-resolution visualization of the crystalline lens in vivo in the eyes of people in real-time without impacting the tissue, which can help ophthalmologists get different aspect information of the crystalline lens. The recent works have shown that the AS-OCT images can be used to locate and characterize opacities of different types of cataract quantitatively and accurately [38], [39], as shown in Figure 4.

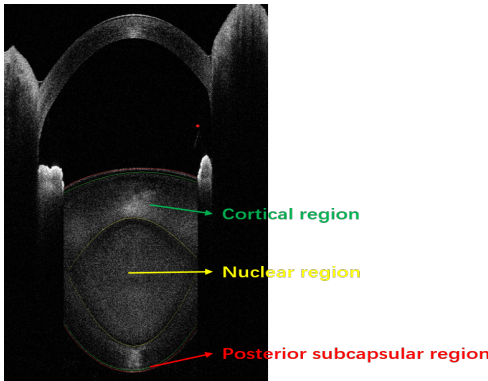


Fig. 4. AS-OCT image. nuclear region is used for NC diagnosis; cortical region is used for CC diagnosis; posterior subcapsular region is used for PSC diagnosis.

Though there are six ophthalmic images, slit lamp images, and fundus images are the most used images for cataract diagnosis. This is because existing cataract classification systems are built on them. However, slit lamp images only capture the nucleus region and cannot capture other regions like the cortex, which is helpful for NC diagnosis. Fundus images only contain opacity information of cataract and do not cataract's location information, which is useful for cataract screening. Retroillumination images are usually used to diagnose CC and PSC clinically, which have not been studied. Digital camera images are ideal ophthalmic images for cataract screening because they can be collected through mobile phones and only have opacity information. Ultrasonic images can capture the lens region, but they can not distinguish different subregions, e.g., cortex. AS-OCT image is a new ophthalmic image that can distinguish different subregions, e.g., cortex in the lens region, which are significant for cataract surgery; yet, there no cataract classification systems are built on them. Hence, it

is urgent to develop a clinical cataract classification system based on AS-OCT images.

### III. CATARACT GRADING SYSTEM

To grade the severity levels of cataract (lens opacities) accurately and quantitatively, it is crucial and necessary to build standard/gold cataract grading systems for clinical practice and scientific research purposes. This section briefly introduces five cataract grading systems.

#### A. Lens Opacity Classification System

Lens Opacity Classification System (LOCS) was first introduced in 1988, which has developed from LOCS I to LOCS III [40]–[42]. LOCS III is widely used for clinical diagnosis and the scientific research. In the LOCS III, as shown in Figure 5, six slit lamp images for nuclear cataract grading based on nuclear color and nuclear opalescence; five retroillumination images for cortical cataract grading; five retroillumination images for grading posterior subcapsular cataract. The severity of cataract is graded on a decimal scale by spacing intervals regularly.

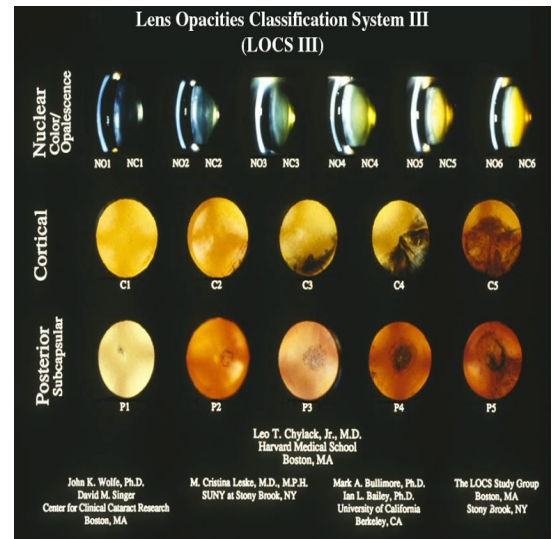


Fig. 5. Lens Opacity Classification System III.

#### B. Wisconsin Grading System

Wisconsin grading system was proposed by the Wisconsin Survey Research Laboratory in 1990 [43]–[45]. It contains four standard photographs for grading cataract severity levels. The grades for cataract severity as follows: grade 1, as clear or clearer than Standard 1; grade 2, not as clear as Standard 1 but as clear or clearer than Standard 2; grade 3, not as clear as Standard 2 but as clear or clearer than Standard 3; grade 4, not as clear as Standard 3 but as clear or clearer than Standard 4; grade 5, at least as severe as Standard 4; and grade 6, 7 and 8, cannot grade due to severe opacities of the lens (please see detail introduction of Wisconsin grading system in literature [43]). Wisconsin grading system also uses a decimal grade for cataract grading with 0.1-unit interval space, and the range of the decimal grade is from 0.1 to 4.9.

### C. Oxford Clinical Cataract Classification and Grading System

Oxford Clinical Cataract Classification and Grading System (OCCCGS) is also a slit-lamp based cataract grading system [46], [47]. Different to the LOCS III uses photographic transparencies of the lens as cataract grading standards, it adopts standard diagrams and Munsell color samples to grade the severity of cortical, posterior subcapsular, and nuclear cataract [47]. In the OCCCGS, five standard grading levels are used for evaluating the severity of cataract based on cataract features, such as cortical features, nuclear features, and morphological features, etc. [46]. E.g., the severity levels of nuclear cataract are graded as follows: Grade 0: No yellow detectable; Grade 1: yellow just detectable; Grade 2: definite yellow; Grade 3: orange yellow; Grade 4: reddish brown; Grade 5: blackish brown [46].

### D. Johns Hopkins system

Johns Hopkins system (JHS) was first used in 1980s [48]. It has four standard images, which denotes the severity of cataract based on opalescence of the lens. For nuclear cataract, Grade 1: opacities that are definitely present but not thought to reduce visual acuity; Grade 2: opacities are consistent with a visual acuity between 20/20 and 20/30; Grade 3 opacities are consistent with vision between 20/40 and 20/100; Grade 4: opacities are consistent with vision of 20/200 or less.

### E. WHO Cataract Grading System

WHO Cataract Grading System was developed by a group of experts in WHO [49], [50]. The use of it is to enable relatively inexperienced observers to grade the most common forms of cataract reliably. It uses four levels for grading NC, CC, and PSC based on four standard images.

### F. Fundus based Cataract Classification System

Xu et al. [51] proposed a fundus image-based cataract classification system (FCS) through observing the blur level. They used five levels to evaluate the blur levels on fundus images: grade 0: clear; grade 1: the small vessel region was blurred; grade 2: the larger branches of retinal vein or artery were blurred; grade 3: the optic disc region was blurred; grade 4: The whole fundus image was blurred.

From the above six existing cataract classification systems, we can see that five cataract classification systems are built on slit lamp images, and one is built on fundus images, which explains that most existing works based on these two ophthalmic imaging modalities. However, these systems are subjective due to the limitations of these two images. Furthermore, to improve the precision of cataract diagnosis and the efficiency of cataract surgery, it is necessary and vital to develop new and objective cataract classification systems on other ophthalmic imaging modalities, e.g., AS-OCT images.

## IV. EVALUATION MEASURES

This section introduces evaluation measures to verify the performance of cataract classification and grading. In this paper, Classification denotes the cataract labels used for learning are discrete, e.g., 1,2,3,4, while grading denotes cataract labels are continuous, e.g., 0.1,0.5,1.0, 1.6, 3.3.

For cataract classification, accuracy (ACC), sensitivity (recall), specificity, precision, F1-measure (F1), and G-mean are commonly used to evaluate the classification results. [30], [52], [53].

$$ACC = \frac{TP + TN}{TP + TN + FP + FN}, \quad (1)$$

$$Sensitivity = \frac{TP}{TP + FN}, \quad (2)$$

$$Specificity = \frac{TN}{TN + FP}, \quad (3)$$

$$Precision = \frac{TP}{TP + FP}, \quad (4)$$

$$F1 = \frac{2 * precision * recall}{precision + recall}, \quad (5)$$

$$G - mean = \sqrt{\frac{TP}{TP + FN} * \frac{TN}{TN + FP}}, \quad (6)$$

where TP, FP, TN and FN denote the numbers of true positives, false positives, true negatives and false negatives, respectively. Other evaluation measures like receiver operating characteristic curve (ROC), the area under the ROC curve (AUC), and kappa coefficient [30] are also applied to measure the overall performance.

For grading, the following evaluation measures are used to evaluate the performance, titled the exact integral agreement ratio  $R_0$ , the percentage of decimal grading errors  $\leq 0.5$   $R_{e0.5}$ , the percentage of decimal grading errors  $\leq 1.0$   $R_{e1.0}$ , and the mean absolute error  $\varepsilon$  [11], [54]–[57].

$$R_0 = \frac{|\lceil G_{gt} \rceil = \lceil G_{pr} \rceil|_0}{N}, \quad (7)$$

$$R_{e0.5} = \frac{||G_{gt} - G_{pr}| \leq 0.5|_0}{N}, \quad (8)$$

$$R_{e1.0} = \frac{||G_{gt} - G_{pr}| \leq 1.0|_0}{N}, \quad (9)$$

$$\varepsilon = \frac{\sum |G_{gt} - G_{pr}|}{N}, \quad (10)$$

where  $G_{gt}$  and  $G_{pr}$  denote the ground-truth grade and the predicted grade.  $\lceil \cdot \rceil$  is the ceiling function,  $|\cdot|$  is the absolute function,  $|\cdot|_0$  a function that counts the number of non-zero values, and  $N$  denotes the number of images.

## V. MACHINE LEARNING TECHNIQUES

This section mainly investigates on ML techniques for cataract classification and grading, which is comprised of conventional ML methods and deep learning methods.

TABLE I  
CONVENTIONAL ML METHODS FOR CATARACT DETECTION AND GRADING BASED ON OPHTHALMIC IMAGES.

Literature	Method	Image Type	Year	Application	Cataract Type
[5]	ASM + SVR	Slit Lamp Image	2009	Grading	NC
[58]	ASM + Ranking	Slit Lamp Image	2009	Grading	NC
[59]	ASM + SVR	Slit Lamp Image	2010	Grading	NC
[57]	ASM + Ranking	Slit Lamp Image	2010	Grading	NC
[11]	ASM + LR	Slit Lamp Image	2007	Grading	NC
[55]	SF + SWLR	Slit Lamp Image	2016	Grading	NC
[60]	BOF + GSR	Slit Lamp Image	2013	Grading	NC
[61]	SVM	Slit Lamp Image	2016	Grading	NC
[62]	SVM	Slit Lamp Image	2017	Grading	NC
[63]	SVM	Slit Lamp Image	2017	Grading	NC
[64]	IGB	Slit Lamp Image	2014	Grading	NC
[62]	RF	Slit Lamp Image	2017	Classification	NC
[65]	SRCL	Slit Lamp Image	2018	Grading	NC
[66]	Hough Circular Transform	Slit Lamp Image	2019	Classification	NC
[67]	RF	Slit Lamp Image	2019	Classification	PC
[67]	NB	Slit Lamp Image	2019	Classification	PC
[6]	Canny + Spatial Filter	Retroillumination Image	2010	Classification	PSC
[68]	EF + PCT	Retroillumination Image	2008	Classification	PSC
[69]	Canny	Retroillumination Image	2011	Classification	PSC
[70]	MRF	Retroillumination Image	2017	Classification	PSC
[71]	LDA	Retroillumination Image	2011	Classification	PSC & CC
[72]	Radial-edge & Region-growing	Retroillumination Image	2008	Classification	CC
[73]	PCA	Ultrasonic Image	2015	Classification	Cataract
[73]	Bayes	Ultrasonic Image	2015	Classification	Cataract
[73]	KNN	Ultrasonic Image	2015	Classification	Cataract
[73]	SVM	Ultrasonic Image	2015	Classification	Cataract
[73]	FLD	Ultrasonic Image	2015	Classification	Cataract
[61]	SVM	Ultrasonic Image	2016	Classification	Cataract
[61]	RF	Ultrasonic Image	2016	Classification	Cataract
[61]	Bayes Network	Ultrasonic Image	2016	Classification	Cataract
[74]	PCA + SVM	Ultrasonic Image	2014	Classification	Cataract
[75]	Nakagami Distribution +CRT	Ultrasonic Image	2014	Classification	Cataract
[76]	SVM	Ultrasonic Image	2013	Classification	Cataract
[77]	GLCM + KNN	Digital Camera Image	2015	Classification	Cataract
[78]	GLCM + KNN	Digital Camera Image	2015	Classification	Cataract
[79]	K-Means	Digital Camera Image	2016	Classification	Cataract
[80]	IMF	Digital Camera Image	2016	Classification	Cataract
[81]	SVM	Digital Camera Image	2016	Classification	Cataract
[52]	WT + MDA	Fundus Image	2015	Classification	Cataract
[82]	Wavelet-SVM	Fundus Image	2015	Classification	Cataract
[82]	Texture-SVM	Fundus Image	2015	Classification	Cataract
[82]	Stacking	Fundus Image	2015	Classification	Cataract
[83]	PCA + Bagging	Fundus Image	2015	Classification	Cataract
[83]	PCA + RF	Fundus Image	2015	Classification	Cataract
[84]	Multi-feature Fusion&Stacking	Fundus Image	2019	Classification	Cataract
[83]	PCA + GBDT	Fundus Image	2015	Classification	Cataract
[83]	PCA + SVM	Fundus Image	2015	Classification	Cataract
[30]	Haar Wavelet + Voting	Fundus Image	2019	Classification	Cataract
[85]	SVM + GA	Fundus Image	2017	Classification	Cataract
[86]	AWM + SVM	Fundus Image	2019	Classification	Cataract
[87]	DT	Fundus Image	2016	Classification	Cataract
[87]	Bayesian Network	Fundus Image	2016	Classification	Cataract
[88]	DWT+SVM	Fundus Image	2019	Classification	Cataract
[88]	SSL	Fundus Image	2019	Classification	Cataract
[89]	RF	AS-OCT image	2021	Classification	NC
[89]	SVM	AS-OCT image	2021	Classification	NC

### A. Conventional Machine Learning Methods

Over the past years, researchers have proposed many state-of-the-art conventional ML methods to classify/grade cataract severity levels automatically. These methods usually contain two stages: feature extraction and classification /grading, as shown in Figure 6. Table I summarizes conventional ML methods for cataract classification and grading based on different ophthalmic images.

1) *Feature Extraction*: Given characteristics of different imaging techniques and types of cataract, we introduce feature

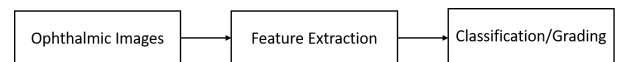


Fig. 6. Flowchart of conventional machine learning based classification and grading.

extraction methods based on types of ophthalmic images.

**Slit Lamp Images.** The procedures to extract features from slit lamp images as follows, as shown in Figure 7: the lens structure detection and feature extraction.

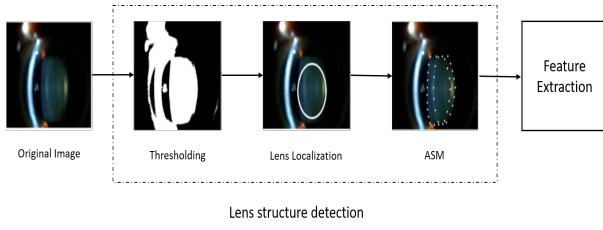


Fig. 7. The procedures to extract image features from slit lamp images for automatic nuclear cataract diagnosis.

First, according to the histogram analysis results of the lens based on slit lamp images, the foreground of the lens is detected by setting pixels' thresholding. The background of the lens images is even. Afterward, the profile on the horizontal median line of the image is analyzed. The largest cluster on the line is detected as the lens, and the centroid of the cluster is detected as the horizontal coordinate of the lens center. Then, we get the profile on the vertical line through the point. Finally, the center of lens is estimated, and the lens can be further estimated as an ellipse with the semi-major axis radius estimated from the horizontal and vertical profile.

Followed by the location of the lens, the lens contour or shape needs to be captured. Researchers used the active shape model (ASM) method for the lens contour detection [6], [59], [68] and achieved 95% accuracy of the lens structure detection based on the ASM method. The ASM can describe the object shape through an iterative refinement procedure to fit an example of the object into a new image based on the statistical models [11]. Based on the detected lens contour, a number of feature extraction methods have been proposed, such as bag-of-features (BOF) method, grading protocol-based method, semantic reconstruction-based method, statistical texture analysis, and so on [6], [55], [58], [60], [64], [71].

**Retroillumination Images.** It contains two steps for feature extraction on retroillumination images: pupil detection and opacity detection [6], [68], [69], [71], as shown in Figure 8. Researchers use a combination of canny edge detection, the Laplacian method, and the convex hull method for the edgel pixel detection in the pupil detection stage. Based on the detected pixels, the non-linear least square fitting method is used to fit an ellipse. In the opacity detection, the input image is transformed into the polar coordinate at first. Based on the polar coordinate, classical image processing methods are applied to detect opacity such as global threshold, local threshold, edge detection, and region growing. Apart from the above methods, literature [70] uses Watershed and Markov random fields (MRF) to detect the lens opacity, and results show that the proposed methods can achieve good results of PSC detection.

**Ultrasound Images & Digital Camera Images & AS-OCT Images.** For ultrasound images, researchers adopt the Fourier Transform (FT) method, textural analysis method, and probability density to extract features [61], [74], [75]. The procedures to extract features from digital camera images is the same to slit lamp images, but different image processing methods are used such as Gabor Wavelet transform, Gray level

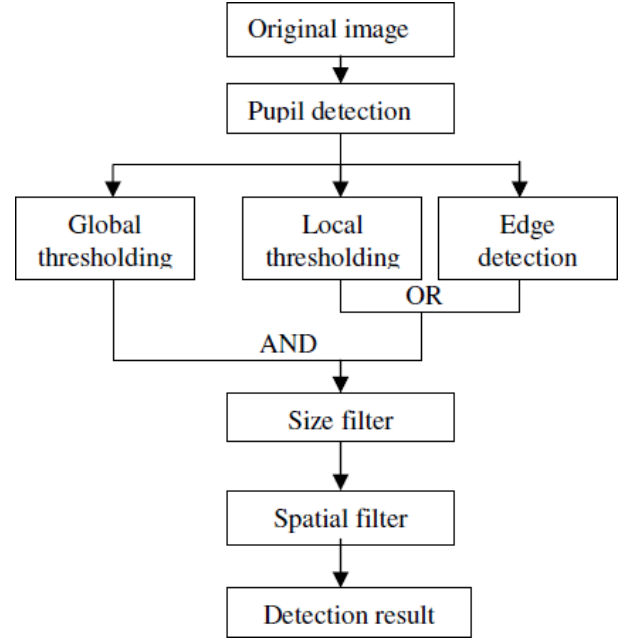


Fig. 8. The procedures to extract features from retroillumination images for cortical cataract (CC) and posterior subcapsular cataract (PSC) diagnosis.

Co-occurrence Matrix (GLCM), image morphological feature, and Gaussian filter [77]–[80]. Literature [89] uses intensity-based statistics method and intensity histogram method to extract image features from AS-OCT images.

**Fundus Images.** For fundus images, various wavelet transform functions are usually used for feature extraction as shown in Fig. 9, such as discrete wavelet transform (DWT), discrete cosine transform (DCT), Haar wavelet transform, and top-bottom hat transformation [12], [30], [52].

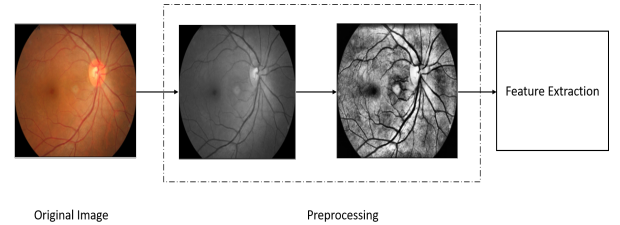


Fig. 9. The procedures to extract features from fundus images for cataract classification or screening.

2) *Classification & Grading:* In this section, we mainly introduce conventional machine learning methods for cataract classification/grading.

**Support Vector Machine.** Support Vector Machine (SVM) is a classical supervised machine learning technique, which can be used for classification and linear regression tasks. It is a popular and efficient learning method for medical imaging applications. For the cataract grading task, Li et al. [5], [59] utilized support vector machine regression (SVR) to grade the severity of cataract and achieved good performance based on slit lamp images. For the cataract classification task, the SVM classifier is widely used in different ophthalmic



images. E.g., literature [62], [63] applies SVM to classify the severity levels of cataract based on slit-lamp images. For other ophthalmic image types, SVM also achieves good results based on different feature extraction methods [81], [82], [82], [85].

**Linear Regression.** Linear regression (LR) is one of the most well-known ML methods and has been used to address different learning tasks. The concept of LR is still a basis for other advanced techniques, like deep neural networks. Linear functions determine its model in LR, whose parameters are learned from data by training. Literature [11] first studies automatic cataract grading with LR on slit lamp images and achieves good grading results. Followed by literature [11], Xu et al. [55], [60] proposed the group sparsity regression (GSR) and similarity weighted linear reconstruction (SWLR) for cataract grading and achieved better grading results.

**k-nearest neighbors.** K-nearest neighbors (KNN) method is a simple, easy-to-implement supervised machine learning technique used for classification and regression tasks. It uses the similarity to classify new cases based on stored instances. Y.N. Fuadah et al. [77] used the KNN to detect cataract on digital camera images and achieved 97.2% accuracy. Literature [73] also uses KNN for cataract classification on Ultrasonic images, which collected from the animal model.

**Ensemble.** Ensemble learning technique uses multiple machine learning methods to solve the same problem and usually obtain better classification performance. Researchers [30], [82], [84] have used several ensemble learning methods for cataract classification such as Stacking, Bagging, and Voting. Compared with single machine learning methods, ensemble learning methods achieved better cataract grading results.

**Ranking.** Ranking denotes a relationship within the list by in a/an descending/ascending order. Researchers [57], [58] applied the ranking strategy to automatic cataract grading by computing the score of each image from the learned ranking function such as RankBoost and Ranking SVM and achieved competitive performance.

**Others.** Apart from the above introduced ML techniques, other efficient ML methods are also used for cataract classification and grading automatically, such as Markov random field (MRF), random forest (RF), Bayesian Network, Linear Discriminant Analysis (LDA), k-means, and decision tree (DT), etc. E.g., literature [70] applies Markov random field (MRF) to automatic CC classification and achieves good results. [88] uses a semi-supervised learning (SSL) framework for cataract classification based on fundus images and achieves competitive performance.

Furthermore, according to Table I, we can summarize as follows.

- For feature extraction, despite their characteristics of ophthalmic images, various image processing techniques are adopted to useful cataract feature extraction, like edge detection method, wavelet transform method, and texture extraction methods, etc. However, no previous works systematically compare these feature extraction methods based on the same ophthalmic image, providing a standard benchmark for other researchers.

- For classification/grading, researchers have used various ML methods to classify cataracts on ophthalmic images and demonstrated that ML methods achieve good performance based on extracted features. No previous literature has made a comparison between ML methods comprehensively based on the same ophthalmic image; hence, it is also necessary to build baselines for cataract classification, and researchers can reproduce previous works.

## B. Deep Learning Methods

In recent years, with the rapid development of deep learning technique, a number of deep learning methods have been applied to many learning tasks, ranging from artificial neural network (ANN), multilayer perceptron (MLP) neural network, back propagation neural network (BPNN), convolutional neural network (CNN), recurrent neural network (RNN), to deep neural network (DNN). Table II provides a summary of deep learning methods for cataract classification and grading based on different ophthalmic images.

1) *Multilayer Perceptron Neural Networks:* Multilayer perceptron (MLP) neural network is one type of artificial neural networks (ANNs), which is composed of multiple hidden layers, as shown in Figure 10. In the MLP, every unit in the current layer is fully connected to every previous layer unit, as shown in Figure ???. Traditional MLP model usually contains a few hidden layers, which is only able to learn from small data. The MLP model is often combined with hand-engineered feature extraction methods for cataract classification. Zhou et al. [12] combined a shallow MLP model with feature extraction methods to classify cataract's severe levels automatically. Caixinha et al. [75] utilized the MLP model for the cataract classification and achieved 96.7% of accuracy. Compared with MLP, deep neural networks (DNNs) contain more hidden layers and is capable of capturing better feature representations from ophthalmic images. DNN usually is used as dense (fully-connected) layers of CNN models. Literature [84], [99], [100] uses DNN models for cataract classification and achieves accuracy over 90%.

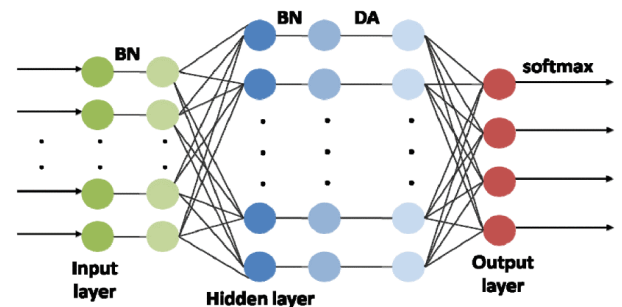


Fig. 10. An example of a multilayer perceptron (MLP) neural network. BN denotes batch normalization; DA denotes uniform or exponential activation function.

2) *Convolutional Neural Networks:* Convolutional neural network (CNN) has been widely used in the ophthalmic image processing field and achieve competitive performance

TABLE II  
DEEP LEARNING METHODS FOR CATARACT CLASSIFICATION AND GRADING ON OPHTHALMIC IMAGES.

Literature	Method	Image Type	Year	Application	Cataract Type
[13]	CNN+RNN	Slit Lamp Image	2015	Grading	NC
[53]	CNN+RNN	Slit Lamp Image	2018	Classification	PCO
[90]	CNN	Slit Lamp Image	2017	Classification	PCO
[91]	CNN	Slit Lamp Image	2019	Classification	NC
[62]	CNN	Slit Lamp Image	2017	Classification	PCO
[10]	CNN	Slit Lamp Image	2017	Classification	Cataract
[92]	CNN	Slit Lamp Image	2018	Classification	Cataract
[93]	Faster R-CNN	Slit Lamp Image	2019	Grading	NC
[94]	CNN	Slit Lamp Image	2019	Classification	NC
[95]	CNN	Slit Lamp Image	2019	Classification	NC
[96]	CNN	Slit Lamp Image	2020	Classification	NC
[97]	CNN	Slit Lamp Image	2021	Classification	Cataract
[98]	Wavelet + ANN	Digital Camera Image	2016	Classification	Cataract
[61]	MLP	Ultrasonic Image	2016	Classification	Cataract
[82]	BPNN	Fundus Image	2015	Classification	Cataract
[84]	FCNN	Fundus Image	2019	Classification	Cataract
[12]	MLP	Fundus Image	2019	Classification	Cataract
[12]	CNN	Fundus Image	2019	Classification	Cataract
[99]	CNN	Fundus Image	2019	Classification	Cataract
[100]	CNN	Fundus Image	2017	Classification	Cataract
[101]	CNN	Fundus Image	2017	Classification	Cataract
[102]	CNN	Fundus Image	2017	Classification	Cataract
[103]	CNN	AS-OCT Image	2020	Classification	NC

[104]–[114]. CNN consists of convolutional layer, pooling layer, and fully-connected layer, as shown in Figure ???. The convolutional layer's function is to learn high-level feature representations from the input features through many convolution operations, as shown in Figure.

For slit lamp images, most previous works usually used classical image processing methods to localize the region of interest (ROI) of the lens, and the lens ROI is used as the inputs features of CNN models [90], [93], [115]. E.g., Liu et al. [90] proposed a CNN model to detect and grade the severe levels of posterior capsular opacification (PCO), which used the lens ROI as the inputs of CNN. Literature [93] uses original images as inputs for CNN models to detect and grade cataract automatically through Faster R-CNN. Literature [10] develops an artificial intelligence platform for congenital cataract diagnosis and obtains good diagnosis results. Literature [95] propose an universal artificial intelligence platform for nuclear cataract management and achieves good results. For fundus images, literature [84], [99]–[101] achieve good classification results. To improve the interpretability of CNN models, Zhou et al. [12] proposed the EDST-ResNet model for cataract classification based on fundus images where they used discrete state transition function [116] as the activation function. For AS-OCT images, literature [117]–[119] proposes convolution neural network frameworks for automatic lens region segmentation based on AS-OCT images, which can help ophthalmologists localize and diagnose different types of cataract efficiently. Zhang et al. [103] proposed a novel CNN model named GraNet for nuclear cataract classification on AS-OCT images but achieved poor results.

3) *Hybrid Neural Networks*: The hybrid neural network denotes a network model that is comprised of two types or more than two types of deep learning frameworks. In recent years, researchers have gradually proposed hybrid deep learning models for different learning tasks [53]. They wanted

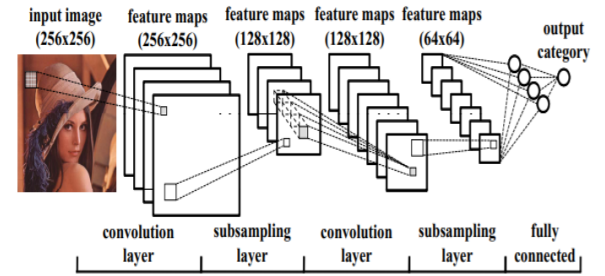


Fig. 11. An example of a convolutional neural network (CNN) for classifying images [120].

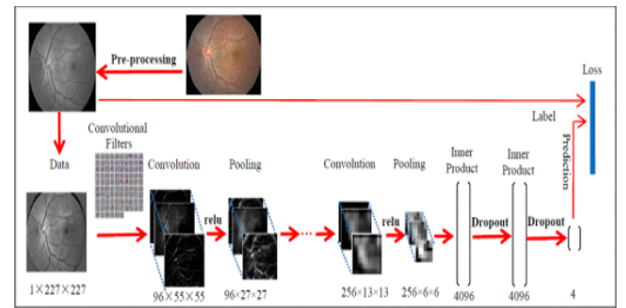


Fig. 12. An example of a convolutional neural network (CNN) model for cataract classification on fundus image [101].

to take advantage of different neural network architectures to get better feature representations for learning tasks. Literature [13], [53] proposes the hybrid neural network models for cataract classification and grading, respectively. In their research, they combined a convolutional neural network (CNN) model with a recurrent neural network (RNN) model, which can learn relationships among inner feature maps and consider



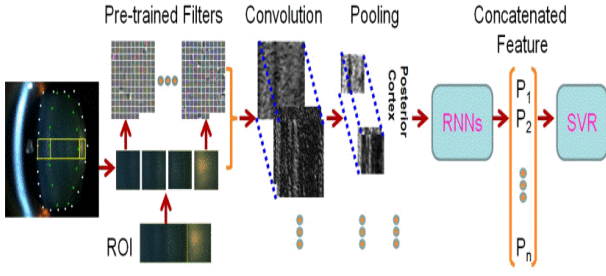


Fig. 13. A hybrid neural network model for nuclear cataract grading on slit lamp images, comprised of a CNN model and a RNN model [13].

the relationship among feature maps. In the future, we hope that more advanced hybrid neural network models will be proposed for cataract classification and grading.

From table I and table II, we can conclude as follows:

- Slit lamp images and fundus images account for most automatic cataract classification and grading works, because these two ophthalmic imaging modalities are easy to access, and they also have clinical cataract grading and classification systems.
- Except for ultrasound images collected the animal model, other five ophthalmic imaging modalities automatic cataract classification and grading for from human subjects.
- From 2015, researchers have gradually used deep learning methods for automatic cataract classification and grading. Compared with conventional machine learning methods, deep learning methods usually get better performance. However, conventional machine learning methods are still widely adopted due to good interpretability.
- According to table II, CNN-based models account for over 50% deep learning methods, because current cataract diagnosis highly relies on ophthalmic images. To enhance precision of cataract diagnosis, it is better to combine image data with non-imaging data, e.g., age.
- Most published works can achieve about 80% accuracy and mainly focused on cataract screening.
- Cataract classification task accounts for most automatic cataract classification and grading works, because discrete labels are easy to access.
- most existing methods used supervised learning methods for automatic cataract classification and grading, and only two research works used semi-supervised learning methods. In the future work, we can adopt unsupervised learning and semi-supervised learning methods for cataract diagnosis.

## VI. CHALLENGES AND POSSIBLE SOLUTIONS

Although researchers have made great development in automatic cataract classification and grading over the years, there are still challenges in this field. This section presents these challenges and gives possible solutions.

### A. Lacking Public Cataract Datasets

Public cataract datasets are a very critical issue for cataract classification and grading. Previous works have made tremen-

dous progress in automatic cataract/grading [52], [60], [74], [121], there is no public and standard ophthalmology image dataset available except for public challenges datasets. Hence, it is difficult for researchers to follow previous works because the cataract dataset is unavailable. To this problem, it is necessary and significant to build public and standard ophthalmology image datasets based on standardized medical data collection and storage protocol. Public cataract datasets can be collected from hospitals and clinics with ophthalmologists' help. This dataset collection mode can ensure the quality and diversity of cataract data and help researchers develop more advanced ML methods.

### B. Developing Standard Cataract Grading Protocols for New Ophthalmic Imaging Modalities

Most existing works use the LOCS III as the clinical gold diagnosis standard to grade cataract severity levels in scientific research and clinical practice. However, the LOCS III is developed based on slit-lamp images, which may not work well for ophthalmic images such as AS-OCT images and Ultrasonic images. To solve this problem, researchers have made much effort. E.g., for fundus images, researchers refer to the WHO Cataract Grading System and develop a cataract grading protocol [51] based on clinical research and practice, which is widely used in automatic fundus-based cataract classification [84], [99]–[101].

To address the issue of developing standard cataract grading protocols for new ophthalmic imaging modalities, e.g., AS-OCT images. In this paper, we propose two possible solutions for reference as follows.

- Developing a cataract grading protocol based on clinical verification. E.g., for ASOCT images, literature [38], [39] has analyzed the lens opacities of patients for comparing the severity levels of cataract based on the LOCS III in clinical practice, which may provide clinical support and reference. Hence, it is likely to develop a referenced cataract grading protocol for ASOCT images based on clinical verification like the LOCS III.
- Building the mapping relationship between two ophthalmic imaging modalities. The lens opacities are an important indicator to measure the severity of cataract, which can be presented on different ophthalmic images through different forms in clinical research. Therefore, it is potential to construct the mapping relationship between two different ophthalmic imaging modalities for developing a new cataract grading protocol by comparing the lens opacities, e.g., fundus image-based cataract grading classification and WHO Cataract Grading System.

Furthermore, to verify the effectiveness of new standard cataract grading protocols, we would collect multiple center data from different hospitals.

### C. How to Annotate Cataract Images Accurately

Data annotation is a challenging problem for the medical image field includes cataract images, which is the base for accurate ML-based disease diagnosis. It is impossible for

ophthalmologists to label massive cataract images manually [122], [123], because it is expensive and time-consuming.

Literature [87], [88] uses the semi-supervised learning strategy for cataract grading based on fundus images and achieves good results. It is probably to utilize weakly supervised learning to learn useful information from labeled cataract images and let the machine label unlabeled cataract images based on learned information automatically. The recent works showed that deep clustering methods can help researchers acquire labels positively rather than acquire labels negatively [124]–[128]. We can apply deep clustering methods to label cataract images in the future actively. Moreover, content-based image retrieval (CBIR) [129]–[131] technique has been widely used for different tasks based on different image features. It also can be utilized to annotate cataract images by comparing testing images with standard images.

#### ***D. How to Classify and Grade Cataracts Accurately for Clinical Diagnosis***

As previously introduced, most previous works focused on cataract screening, few previous works paid attention to clinical cataract diagnosis, especially for cataract surgery planning. Different severe cataracts and different cataract types should take corresponding treatments in clinics. Cataracts are associated with various factors [132] and the lens's regions [38], [39], [55], [71], [73], which can be considered as domain knowledge. We can combine the domain knowledge with ophthalmic images for automatic cataract classification and grading. Literature [117], [118] proposes the deep learning framework for the lens region segmentation based on AS-OCT images, a base for different cataract diagnosis types. It is possible to use a joint segmentation and classification learning framework for multiple cataract classification types in the future. Furthermore, researchers have used transfer learning strategies to improve the cataract classification results based on fundus images [93], [101]. Hence, we can also utilize transfer learning strategies for multiple types of cataract detection and grading based on existing multi-task deep learning frameworks.

Previous works only used one type of ophthalmic image for the diagnosis of cataract [55], [71], [73], [133], and multimodality learning [134]–[137] have been utilized to tackle different medical image tasks, which can be used for automatic cataract classification and grading based on multi-ophthalmic images or the combination of ophthalmic images and non image data. Multi-modality data can be classified into image data and non-image data. However, in current, it is difficult for us to use multi-modality images for automatic cataract classification. Two reasons can account for it: 1) only silt lamp images and fundus images have standard cataract classification systems, which have no correlation relationship between them; 2) existing classification systems are subjective, it is challenging for clinicians to label two cataract severity levels correctly for different ophthalmic images. Furthermore, it is possible for us to combine image data and non-image data for automatic cataract diagnosis because it is easy to collect non-image data such as age and sex, which are associated

with cataracts. Furthermore, recent studies have [138], [139] have used non-image data for PC and PCO diagnosis, which demonstrated that it is potential to use multimodality data to improve the precision of cataract diagnosis.

Image noise is an important factor in affecting automatic cataract diagnosis on ophthalmic images. Researchers have proposed different methods to remove the noise from the images based on the characteristics of ophthalmic images, such as Gaussian filter, discrete wavelet transform (DWT), discrete cosine transform (DCT), Haar wavelet transform and its variants [12], [52], [78]. Additionally, recent research has begun to use the GAN model for medical image denoising and achieved good results.

#### ***E. Improving the Interpretability of Deep Learning Methods***

Deep learning methods have been widely used for cataract classification and grading. Deep learning methods are still considered a black box without explaining why they make good prediction results or poor prediction results. Therefore, it is necessary to give reliable explanations for the predicted results based on deep learning methods. Literature [12] visualizes weight distributions of deep convolutional layers and dense layers to explain the predicted results of deep learning methods. It is likely to analyze the similarities between the weights of convolutional layers to describe the predicted results. [118] indicated that introducing domain knowledge can improve the cataract segmentation results based on AS-OCT images and the deep learning model's interpretability. It is promising for researchers to combine deep learning methods with different domain knowledge to enhance deep learning methods' interpretability. Modern neural networks [140] usually are poorly calibrated, [141] indicated that improving the confidence of predicted probability can explain the predicted results. It is a potential solution for researchers to enhance interpretability by enhancing the confidence of predicted probability.

Moreover, researchers have achieved great progresses for interpretability of deep learning methods in computer vision field. [142]–[145] used the heat maps to localize discriminative regions where CNNs learned. Hinton et al. [146] proposed the correlation analysis technique to analyze similarities of neural network representations to explain what neural networks had learned. These interpretability techniques also used for deep learning based cataract classification works.

#### ***F. Mobile Cataract Screening***

In the past years, researchers have used digital camera images for cataract screening based on ML techniques and have achieved good results [77]–[80], [147]–[149]. Digital camera images can be accessed through mobile phones, which are widely used now. Hence, there are endless potentials to embed powerful digital cameras into mobile phones for cataract screening. Although deep learning methods can achieve excellent cataract screening results, the parameters of them are too much. One possible solution is to develop lightweight deep learning models. Researchers have done a lot of works on designing lightweight deep learning methods over the years [150]–[152]. These works demonstrated that deep

learning methods kept a good balance between accuracy and speed, which are important references for developing cataract screening-based lightweight deep learning methods.

## VII. CONCLUSION

Automatic and objective cataract classification and grading is an important and hot research topic, helping reduce blindness ratio and improve life quality. In this paper, we survey the recent advances in the ML-based cataract classification and grading on ophthalmic imaging modalities, and highlight two research fields: conventional ML methods and deep learning methods. Though ML techniques have made significant progress in cataract classification and grading, there is still room for improvement. First, public cataract ophthalmic images are in need, which can help to build ML baselines. Secondly, automatic ophthalmic image annotation has not been studied seriously and is a potential research direction. Thirdly, developing accurate and objective ML methods for clinical cataract diagnosis, which is an efficient method to help more people improve vision. It is necessary and vital to enhance the interpretability of deep learning, which can prompt the wide use of them in cataract diagnosis. Finally, previous works have used digital camera images for cataract screening, which is a good idea by devising lightweight ML techniques that address the cataract screening problem for developing countries with limited access to expensive ophthalmic devices.

## APPENDIX A

CAD: computer aided diagnosis; ML: machine learning; WHO: World Health Organization; NC: nuclear cataract; CC: cortical cataract; PSC: posterior subcapsular cataract; LR: linear regression ; RF: random forest; SVR: support vector machine regression; ASM: active shape model; NLP: natural language processing; OCT: optical coherence tomography; LOCS: Lens Opacity Classification System; OCCCOS: Oxford Clinical Cataract Classification and Grading System; SVM: support vector machine; artificial intelligent: AI; BOF: bag-of-features; PCA: principal component analysis; DWT: discrete wavelet transform; DCT: discrete cosine transform; KNN: K-nearest neighbor; ANN: artificial neural network; BPNN: back propagation neural network; CNN: convolutional neural network; RNN: recurrent neural network; DNN: deep neural network; MLP: multilayer perceptron; ROI: region of interest; AE: autoencoder; GAN: generative adversarial network; CBIR: content-based image retrieval; ASOCT: anterior segment optical coherence tomography; 3D: three-dimensional; 2D: two-dimensional; SSL: Semi-supervised learning; AWM: Adaptive window model; GSR: Group Sparsity Regression; GLCM: gray level Co-occurrence matrix; Image morphological feature: IMF; SWLR: Similarity Weighted Linear Reconstruction

## REFERENCES

- [1] R. R. Bourne, S. R. Flaxman, T. Braithwaite, M. V. Cicinelli, A. Das, J. B. Jonas, J. Keeffe, J. H. Kempen, J. Leasher, H. Limburg *et al.*, "Magnitude, temporal trends, and projections of the global prevalence of blindness and distance and near vision impairment: a systematic review and meta-analysis," *The Lancet Global Health*, vol. 5, no. 9, pp. e888–e897, 2017.
- [2] D. Pascolini and S. P. Mariotti, "Global estimates of visual impairment: 2010," *British Journal of Ophthalmology*, vol. 96, no. 5, pp. 614–618, 2012.
- [3] P. A. Asbell, I. Dualan, J. Mindel, D. Brocks, M. Ahmad, and S. Epstein, "Age-related cataract," *The Lancet*, vol. 365, no. 9459, pp. 599–609, 2005.
- [4] Y.-C. Liu, M. Wilkins, T. Kim, B. Malyugin, and J. S. Mehta, "Cataracts," *The Lancet*, vol. 390, no. 10094, pp. 600–612, 2017.
- [5] H. Li, J. H. Lim, J. Liu, D. W. K. Wong, N. M. Tan, S. Lu, Z. Zhang, and T. Y. Wong, "An automatic diagnosis system of nuclear cataract using slit-lamp images," in *2009 Annual International Conference of the IEEE Engineering in Medicine and Biology Society*. IEEE, 2009, pp. 3693–3696.
- [6] H. Li, J. H. Lim, J. Liu, D. W. K. Wong, Y. Foo, Y. Sun, and T. Y. Wong, "Automatic detection of posterior subcapsular cataract opacity for cataract screening," in *2010 Annual International Conference of the IEEE Engineering in Medicine and Biology*. IEEE, 2010, pp. 5359–5362.
- [7] M. Chew, P. P.-C. Chiang, Y. Zheng, R. Lavanya, R. Wu, S. M. Saw, T. Y. Wong, and E. L. Lamoureux, "The impact of cataract, cataract types, and cataract grades on vision-specific functioning using rasch analysis," *American journal of Ophthalmology*, vol. 154, no. 1, pp. 29–38, 2012.
- [8] C. Delcourt, J.-P. Cristol, F. Tessier, C. L. Leger, F. Michel, L. Papoz, and P. S. Group, "Risk factors for cortical, nuclear, and posterior subcapsular cataracts: the pola study," *American journal of epidemiology*, vol. 151, no. 5, pp. 497–504, 2000.
- [9] W. L. Wong, X. Li, J. Li, C.-Y. Cheng, E. L. Lamoureux, J. J. Wang, C. Y. Cheung, and T. Y. Wong, "Cataract Conversion Assessment using Lens Opacity Classification System III and Wisconsin Cataract Grading System," *Investigative Ophthalmology & Visual Science*, vol. 54, no. 1, pp. 280–287, 01 2013. [Online]. Available: <https://doi.org/10.1167/iovs.12-10657>
- [10] E. Long, H. Lin, Z. Liu, X. Wu, L. Wang, J. Jiang, Y. An, Z. Lin, X. Li, J. Chen *et al.*, "An artificial intelligence platform for the multihospital collaborative management of congenital cataracts," *Nature biomedical engineering*, vol. 1, no. 2, pp. 1–8, 2017.
- [11] H. Li, J. H. Lim, J. Liu, and T. Y. Wong, "Towards automatic grading of nuclear cataract," in *2007 29th Annual International Conference of the IEEE Engineering in Medicine and Biology Society*. IEEE, 2007, pp. 4961–4964.
- [12] Y. Zhou, G. Li, and H. Li, "Automatic cataract classification using deep neural network with discrete state transition," *IEEE transactions on medical imaging*, 2019.
- [13] X. Gao, S. Lin, and T. Y. Wong, "Automatic feature learning to grade nuclear cataracts based on deep learning," *IEEE Transactions on Biomedical Engineering*, vol. 62, no. 11, pp. 2693–2701, 2015.
- [14] Z. Zhang, R. Srivastava, H. Liu, X. Chen, L. Duan, D. W. K. Wong, C. K. Kwok, T. Y. Wong, and J. Liu, "A survey on computer aided diagnosis for ocular diseases," *BMC medical informatics and decision making*, vol. 14, no. 1, p. 80, 2014.
- [15] I. Shaheen and A. Tariq, "Survey analysis of automatic detection and grading of cataract using different imaging modalities," in *Applications of Intelligent Technologies in Healthcare*. Springer, 2019, pp. 35–45.
- [16] H. I. M. Lopez, J. C. S. Garcia, and J. A. D. Mendez, "Cataract detection techniques: A review," *IEEE Latin America Transactions*, vol. 14, no. 7, pp. 3074–3079, 2016.
- [17] R. Zafar, M. Sharif, and M. Yasmin, "A survey on the prevalence of cataract and its accompanying risk factors," *Current Medical Imaging Reviews*, vol. 14, no. 2, pp. 251–262, 2018.
- [18] H. E. Gali, R. Sella, and N. A. Afshari, "Cataract grading systems: a review of past and present," *Current opinion in ophthalmology*, vol. 30, no. 1, pp. 13–18, 2019.
- [19] J. H. L. Goh, Z. W. Lim, X. Fang, A. Anees, S. Nusinovi, T. H. Rim, C.-Y. Cheng, and Y.-C. Tham, "Artificial intelligence for cataract detection and management," *The Asia-Pacific Journal of Ophthalmology*, vol. 9, no. 2, pp. 88–95, 2020.
- [20] A. F. Fercher, H. C. Li, and C. K. Hitzinger, "Slit lamp laser doppler interferometer," *Lasers in Surgery and Medicine*, vol. 13, no. 4, pp. 447–452, 1993.
- [21] S. R. Waltman and H. E. Kaufman, "A new objective slit lamp fluorophotometer," *Invest Ophthalmol*, vol. 9, no. 4, pp. 247–249, 1970.
- [22] M. Vivino, A. Mahurkar, B. Trus, M. Lopez, and M. Datiles, "Quantitative analysis of retroillumination images," *Eye*, vol. 9, no. 1, p. 77, 1995.

- [23] A. Gershenzon and L. Robman, "New software for lens retro-illumination digital image analysis," *Australian and New Zealand Journal of Ophthalmology*, vol. 27, no. 3-4, pp. 170-172, 1999.
- [24] C.-C. Huang, R. Chen, P.-H. Tsui, Q. Zhou, M. S. Humayun, and K. K. Shung, "Measurements of attenuation coefficient for evaluating the hardness of a cataract lens by a high-frequency ultrasonic needle transducer," *Physics in Medicine & Biology*, vol. 54, no. 19, p. 5981, 2009.
- [25] C.-C. Huang, H. Ameri, C. DeBoer, A. P. Rowley, X. Xu, L. Sun, S.-H. Wang, M. S. Humayun, and K. K. Shung, "Evaluation of lens hardness in cataract surgery using high-frequency ultrasonic parameters in vitro," *Ultrasound in medicine & biology*, vol. 33, no. 10, pp. 1609-1616, 2007.
- [26] P.-H. Tsui and C.-C. Chang, "Imaging local scatterer concentrations by the nakagami statistical model," *Ultrasound in medicine & biology*, vol. 33, no. 4, pp. 608-619, 2007.
- [27] P.-H. Tsui, C.-K. Yeh, Y.-Y. Liao, C.-C. Chang, W.-H. Kuo, K.-J. Chang, and C.-N. Chen, "Ultrasonic nakagami imaging: A strategy to visualize the scatterer properties of benign and malignant breast tumors," *Ultrasound in Medicine & Biology*, vol. 36, no. 2, pp. 209 - 217, 2010. [Online]. Available: <http://www.sciencedirect.com/science/article/pii/S0301562909015622>
- [28] P.-H. Tsui, C.-C. Huang, C.-C. Chang, S.-H. Wang, and K. K. Shung, "Feasibility study of using high-frequency ultrasonic nakagami imaging for characterizing the cataract lens in vitro," *Physics in Medicine & Biology*, vol. 52, no. 21, p. 6413, 2007.
- [29] P.-H. Tsui, M.-C. Ho, D.-I. Tai, Y.-H. Lin, C.-Y. Wang, and H.-Y. Ma, "Acoustic structure quantification by using ultrasound nakagami imaging for assessing liver fibrosis," *Scientific reports*, vol. 6, p. 33075, 2016.
- [30] L. Cao, H. Li, Y. Zhang, L. Zhang, and L. Xu, "Hierarchical method for cataract grading based on retinal images using improved haar wavelet," *Information Fusion*, vol. 53, pp. 196-208, 2020.
- [31] A. Plesch, U. Klingbeil, and J. Bille, "Digital laser scanning fundus camera," *Applied optics*, vol. 26, no. 8, pp. 1480-1486, 1987.
- [32] O. Pomerantzef, R. H. Webb, and F. C. Delori, "Image formation in fundus cameras," *Investigative ophthalmology & visual science*, vol. 18, no. 6, pp. 630-637, 1979.
- [33] M. Ang, M. Baskaran, R. M. Werkmeister, J. Chua, D. Schmidl, V. A. dos Santos, G. Garhöfer, J. S. Mehta, and L. Schmetterer, "Anterior segment optical coherence tomography," *Progress in Retinal and Eye Research*, vol. 66, pp. 132 - 156, 2018. [Online]. Available: <http://www.sciencedirect.com/science/article/pii/S135094621730085X>
- [34] R. M. Werkmeister, S. Sapeta, D. Schmidl, G. Garhöfer, G. Schmidinger, V. A. dos Santos, G. C. Aschinger, I. Baumgartner, N. Pircher, F. Schwarzhans *et al.*, "Ultrahigh-resolution oct imaging of the human cornea," *Biomedical optics express*, vol. 8, no. 2, pp. 1221-1239, 2017.
- [35] N. Hirschall, S. Amir-Asgari, S. Maedel, and O. Findl, "Predicting the postoperative intraocular lens position using continuous intraoperative optical coherence tomography measurements," *Investigative ophthalmology & visual science*, vol. 54, no. 8, pp. 5196-5203, 2013.
- [36] N. Yamazaki, A. Kobayashi, H. Yokogawa, Y. Ishibashi, Y. Oikawa, M. Tokoro, and K. Sugiyama, "In vivo imaging of radial keratoneuritis in patients with acanthamoeba keratitis by anterior-segment optical coherence tomography," *Ophthalmology*, vol. 121, no. 11, pp. 2153-2158, 2014.
- [37] N. Hirschall, T. Buehren, F. Bajramovic, M. Trost, T. Teuber, and O. Findl, "Prediction of postoperative intraocular lens tilt using swept-source optical coherence tomography," *Journal of Cataract & Refractive Surgery*, vol. 43, no. 6, pp. 732-736, 2017.
- [38] I. Grulkowski, S. Manzanera, L. Cwiklinski, J. Mompeán, A. de Castro, J. M. Marin, and P. Artal, "Volumetric macro- and micro-scale assessment of crystalline lens opacities in cataract patients using long-depth-range swept source optical coherence tomography," *Biomed. Opt. Express*, vol. 9, no. 8, pp. 3821-3833, Aug 2018. [Online]. Available: <http://www.osapublishing.org/boe/abstract.cfm?URI=boe-9-8-3821>
- [39] D. Pawliczek, C. Dalke, H. Fuchs, V. Gailus-Durner, M. H. de Angelis, J. Graw, and O. V. Amarie, "Spectral domain-optical coherence tomography (sd-oct) as a monitoring tool for alterations in mouse lenses," *Experimental eye research*, vol. 190, p. 107871, 2020.
- [40] L. T. Chylack, J. K. Wolfe, D. M. Singer, M. C. Leske, M. A. Bullimore, I. L. Bailey, J. Friend, D. McCarthy, and S.-Y. Wu, "The lens opacities classification system iii," *Archives of ophthalmology*, vol. 111, no. 6, pp. 831-836, 1993.
- [41] L. T. Chylack, M. C. Leske, R. Sperduto, P. Khu, and D. McCarthy, "Lens opacities classification system," *Archives of Ophthalmology*, vol. 106, no. 3, pp. 330-334, 1988.
- [42] L. T. Chylack, M. C. Leske, D. McCarthy, P. Khu, T. Kashiwagi, and R. Sperduto, "Lens opacities classification system ii (locs ii)," *Archives of ophthalmology*, vol. 107, no. 7, pp. 991-997, 1989.
- [43] B. E. K. Klein, R. Klein, K. L. P. Linton, Y. L. Magli, and M. W. Neider, "Assessment of cataracts from photographs in the beaver dam eye study," *Ophthalmology*, vol. 97, no. 11, pp. 1428-1433, 1990.
- [44] A.-R. E. D. S. R. Group *et al.*, "The age-related eye disease study (areds) system for classifying cataracts from photographs: Areds report no. 4," *American journal of ophthalmology*, vol. 131, no. 2, pp. 167-175, 2001.
- [45] S. Fan, C. R. Dyer, L. Hubbard, and B. Klein, "An automatic system for classification of nuclear sclerosis from slit-lamp photographs," in *Medical Image Computing and Computer-Assisted Intervention - MICCAI 2003*, R. E. Ellis and T. M. Peters, Eds. Berlin, Heidelberg: Springer Berlin Heidelberg, 2003, pp. 592-601.
- [46] J. Sparrow, A. Bron, N. Brown, W. Ayliffe, and A. Hill, "The oxford clinical cataract classification and grading system," *International ophthalmology*, vol. 9, no. 4, pp. 207-225, 1986.
- [47] A. Hall, J. Thompson, J. Deane, and A. Rosenthal, "Locs iii versus the oxford clinical cataract classification and grading system for the assessment of nuclear, cortical and posterior subcapsular cataract," *Ophthalmic epidemiology*, vol. 4, no. 4, pp. 179-194, 1997.
- [48] S. K. West, F. Rosenthal, H. Newland, and H. Taylor, "Use of photographic techniques to grade nuclear cataracts," *Investigative ophthalmology & visual science*, vol. 29, no. 1, pp. 73-77, 1988.
- [49] B. Thylefors, L. Chylack Jr, K. Konyama, K. Sasaki, R. Sperduto, H. Taylor, and S. West4, "A simplified cataract grading system the who cataract grading group," *Ophthalmic epidemiology*, vol. 9, no. 2, pp. 83-95, 2002.
- [50] W. P. for the Prevention of Blindness and W. C. G. Group, "A simplified cataract grading system," p. English and French text on inverted pagings, 2001.
- [51] L. Xu, C. W. Yang, H. Yang, S. Wang, Y. Y. Shi, and X. D. Song, "The study of predicting the visual acuity after phacoemulsification according to the blur level of fundus photography," vol. 19, no. 2, pp. 81-83, 2010.
- [52] L. Guo, J.-J. Yang, L. Peng, J. Li, and Q. Liang, "A computer-aided healthcare system for cataract classification and grading based on fundus image analysis," *Computers in Industry*, vol. 69, pp. 72-80, 2015.
- [53] J. Jiang, X. Liu, L. Liu, S. Wang, E. Long, H. Yang, F. Yuan, D. Yu, K. Zhang, L. Wang *et al.*, "Predicting the progression of ophthalmic disease based on slit-lamp images using a deep temporal sequence network," *PloS one*, vol. 13, no. 7, p. e0201142, 2018.
- [54] C. Y.-I. Cheung, H. Li, E. L. Lamoureux, P. Mitchell, J. J. Wang, A. G. Tan, L. K. Johari, J. Liu, J. H. Lim, T. Aung *et al.*, "Validity of a new computer-aided diagnosis imaging program to quantify nuclear cataract from slit-lamp photographs," *Investigative ophthalmology & visual science*, vol. 52, no. 3, pp. 1314-1319, 2011.
- [55] Y. Xu, L. Duan, D. W. K. Wong, T. Y. Wong, and J. Liu, "Semantic reconstruction-based nuclear cataract grading from slit-lamp lens images," in *International Conference on Medical Image Computing and Computer-Assisted Intervention*. Springer, 2016, pp. 458-466.
- [56] Huiqi Li, Joo Hwee Lim, Jiang Liu, D. Wing Kee Wong, and T. Y. Wong, "Computer aided diagnosis of nuclear cataract," in *2008 3rd IEEE Conference on Industrial Electronics and Applications*, June 2008, pp. 1841-1844.
- [57] W. Huang, K. L. Chan, H. Li, J. H. Lim, J. Liu, and T. Y. Wong, "A computer assisted method for nuclear cataract grading from slit-lamp images using ranking," *IEEE Transactions on Medical Imaging*, vol. 30, no. 1, pp. 94-107, 2010.
- [58] W. Huang, H. Li, K. L. Chan, J. H. Lim, J. Liu, and T. Y. Wong, "A computer-aided diagnosis system of nuclear cataract via ranking," in *International Conference on Medical Image Computing and Computer-Assisted Intervention*. Springer, 2009, pp. 803-810.
- [59] H. Li, J. H. Lim, J. Liu, P. Mitchell, A. G. Tan, J. J. Wang, and T. Y. Wong, "A computer-aided diagnosis system of nuclear cataract," *IEEE Transactions on Biomedical Engineering*, vol. 57, no. 7, pp. 1690-1698, 2010.
- [60] Y. Xu, X. Gao, S. Lin, D. W. K. Wong, J. Liu, D. Xu, C. Y. Cheng, C. Y. Cheung, and T. Y. Wong, "Automatic grading of nuclear cataracts from slit-lamp lens images using group sparsity regression," in *International Conference on Medical Image Computing and Computer-Assisted Intervention*. Springer, 2013, pp. 468-475.

- [61] M. Caixinha, J. Amaro, M. Santos, F. Perdigão, M. Gomes, and J. Santos, "In-vivo automatic nuclear cataract detection and classification in an animal model by ultrasounds," *IEEE Transactions on Biomedical Engineering*, vol. 63, no. 11, pp. 2326–2335, 2016.
- [62] J. Jiang, X. Liu, K. Zhang, E. Long, L. Wang, W. Li, L. Liu, S. Wang, M. Zhu, and J. Cui, "Automatic diagnosis of imbalanced ophthalmic images using a cost-sensitive deep convolutional neural network," *Biomedical Engineering Online*, vol. 16, no. 1, p. 132, 2017.
- [63] L. Wang, K. Zhang, X. Liu, E. Long, J. Jiang, Y. An, J. Zhang, Z. Liu, Z. Lin, X. Li *et al.*, "Comparative analysis of image classification methods for automatic diagnosis of ophthalmic images," *Scientific reports*, vol. 7, p. 41545, 2017.
- [64] R. Srivastava, X. Gao, F. Yin, D. W. Wong, J. Liu, C. Y. Cheung, and T. Y. Wong, "Automatic nuclear cataract grading using image gradients," *Journal of Medical Imaging*, vol. 1, no. 1, p. 014502, 2014.
- [65] J. Cheng, "Sparse range-constrained learning and its application for medical image grading," *IEEE Transactions on Medical Imaging*, vol. 37, no. 12, pp. 2729–2738, 2018.
- [66] A. Jagadale, S. Sonavane, and D. Jadav, "Computer aided system for early detection of nuclear cataract using circle hough transform," in *2019 3rd International Conference on Trends in Electronics and Informatics (ICOEI)*. IEEE, 2019, pp. 1009–1012.
- [67] Kai, Zhang, Xiyang, Liu, Jiewei, Jiang, Wangting, Shuai, Wang, and Lin, "Prediction of postoperative complications of pediatric cataract patients using data mining," *Journal of Translational Medicine*, 2019.
- [68] H. Li, L. Ko, J. H. Lim, J. Liu, D. W. K. Wong, T. Y. Wong, and Y. Sun, "Automatic opacity detection in retro-illumination images for cortical cataract diagnosis," in *2008 IEEE International Conference on Multimedia and Expo*. IEEE, 2008, pp. 553–556.
- [69] Y. C. Chow, X. Gao, H. Li, J. H. Lim, Y. Sun, and T. Y. Wong, "Automatic detection of cortical and psc cataracts using texture and intensity analysis on retro-illumination lens images," in *2011 Annual International Conference of the IEEE Engineering in Medicine and Biology Society*. IEEE, 2011, pp. 5044–5047.
- [70] W. Zhang and H. Li, "Lens opacity detection for serious posterior subcapsular cataract," *MEDICAL & BIOLOGICAL ENGINEERING & COMPUTING*, vol. 55, no. 5, pp. 769–779, MAY 2017.
- [71] X. Gao, H. Li, J. H. Lim, and T. Y. Wong, "Computer-aided cataract detection using enhanced texture features on retro-illumination lens images," in *2011 18th IEEE International Conference on Image Processing*, 2011, pp. 1565–1568.
- [72] H. Li, L. Ko, J. H. Lim, J. Liu, D. W. K. Wong, and T. Y. Wong, "Image based diagnosis of cortical cataract," in *2008 30th Annual International Conference of the IEEE Engineering in Medicine and Biology Society*. IEEE, 2008, pp. 3904–3907.
- [73] M. Caxinha, E. Velte, M. Santos, F. Perdigão, J. Amaro, M. Gomes, and J. Santos, "Automatic cataract classification based on ultrasound technique using machine learning: a comparative study," *Physics Procedia*, vol. 70, pp. 1221–1224, 2015.
- [74] M. Caixinha, E. Velte, M. Santos, and J. B. Santos, "New approach for objective cataract classification based on ultrasound techniques using multiclass svm classifiers," in *2014 IEEE International Ultrasonics Symposium*. IEEE, 2014, pp. 2402–2405.
- [75] M. Caixinha, D. A. Jesus, E. Velte, M. J. Santos, and J. B. Santos, "Using ultrasound backscattering signals and nakagami statistical distribution to assess regional cataract hardness," *IEEE Transactions on Biomedical Engineering*, vol. 61, no. 12, pp. 2921–2929, 2014.
- [76] D. Jesus, E. Velte, M. Caixinha, M. Santos, and J. Santos, "Using of the ultrasound frequency dependent attenuation and nakagami distribution for cataract evaluation," in *2013 IEEE 3rd Portuguese Meeting in Bioengineering (ENBENG)*, 2013, pp. 1–4.
- [77] Y. N. Fuadah, A. W. Setiawan, and T. Mengko, "Performing high accuracy of the system for cataract detection using statistical texture analysis and k-nearest neighbor," in *2015 International Seminar on Intelligent Technology and Its Applications (ISITIA)*. IEEE, 2015, pp. 85–88.
- [78] Y. N. Fuadah, A. W. Setiawan, T. L. R. Mengko, and Budiman, "Mobile cataract detection using optimal combination of statistical texture analysis," in *2015 4th International Conference on Instrumentation, Communications, Information Technology, and Biomedical Engineering (ICICI-BME)*, Nov 2015, pp. 232–236.
- [79] S. Pathak and B. Kumar, "A robust automated cataract detection algorithm using diagnostic opinion based parameter thresholding for telemedicine application," *Electronics*, vol. 5, no. 3, p. 57, 2016.
- [80] M. A. U. Patwari, M. D. Arif, M. N. Chowdhury, A. Arefin, and M. I. Imam, "Detection, categorization, and assessment of eye cataracts using digital image processing," in *The first international conference on interdisciplinary research and development*, 2011, pp. 22–1.
- [81] A. A. Khan, M. U. Akram, A. Tariq, F. Tahir, and K. Wazir, "Automated computer aided detection of cataract," in *Proceedings of the Third International Afro-European Conference for Industrial Advancement — AECIA 2016*, A. Abraham, A. Haqiq, A. Ella Hassanien, V. Snasel, and A. M. Alimi, Eds. Cham: Springer International Publishing, 2018, pp. 340–349.
- [82] J.-J. Yang, J. Li, R. Shen, Y. Zeng, J. He, J. Bi, Y. Li, Q. Zhang, L. Peng, and Q. Wang, "Exploiting ensemble learning for automatic cataract detection and grading," *Computer Methods and Programs in Biomedicine*, vol. 124, pp. 45 – 57, 2016. [Online]. Available: <http://www.sciencedirect.com/science/article/pii/S0169260715002679>
- [83] W. Fan, R. Shen, Q. Zhang, J.-J. Yang, and J. Li, "Principal component analysis based cataract grading and classification," in *2015 17th International Conference on E-health Networking, Application & Services (HealthCom)*. IEEE, 2015, pp. 459–462.
- [84] H. Zhang, K. Niu, Y. Xiong, W. Yang, Z. He, and H. Song, "Automatic cataract grading methods based on deep learning," *Computer methods and programs in biomedicine*, vol. 182, p. 104978, 2019.
- [85] Z. Qiao, Q. Zhang, Y. Dong, and J.-J. Yang, "Application of svm based on genetic algorithm in classification of cataract fundus images," in *2017 IEEE International Conference on Imaging Systems and Techniques (IST)*. IEEE, 2017, pp. 1–5.
- [86] C. Huo, F. Akhtar, and P. Li, "A novel grading method of cataract based on awm," in *2019 IEEE 43rd Annual Computer Software and Applications Conference (COMPSAC)*, vol. 2. IEEE, 2019, pp. 368–373.
- [87] W. Song, P. Wang, X. Zhang, and Q. Wang, "Semi-supervised learning based on cataract classification and grading," in *2016 IEEE 40th Annual Computer Software and Applications Conference (COMPSAC)*, vol. 2. IEEE, 2016, pp. 641–646.
- [88] W. Song, Y. Cao, Z. Qiao, Q. Wang, and J.-J. Yang, "An improved semi-supervised learning method on cataract fundus image classification," in *2019 IEEE 43rd Annual Computer Software and Applications Conference (COMPSAC)*, vol. 2. IEEE, 2019, pp. 362–367.
- [89] X. Zhang, J. Fang, Z. Xiao, H. Risa, W. Chen, J. Yuan, and J. Liu, "Research on classification algorithms of nuclear cataract based on anterior segment coherence tomography image," *Computer Science*, 2021.
- [90] X. Liu, J. Jiang, K. Zhang, E. Long, J. Cui, M. Zhu, Y. An, J. Zhang, Z. Liu, Z. Lin *et al.*, "Localization and diagnosis framework for pediatric cataracts based on slit-lamp images using deep features of a convolutional neural network," *PloS one*, vol. 12, no. 3, p. e0168606, 2017.
- [91] T. J. Jun, Y. Eom, C. Kim, D. Kim *et al.*, "Tournament based ranking cnn for the cataract grading," in *2019 41st Annual International Conference of the IEEE Engineering in Medicine and Biology Society (EMBC)*. IEEE, 2019, pp. 1630–1636.
- [92] K. Zhang, X. Liu, F. Liu, L. He, L. Zhang, Y. Yang, W. Li, S. Wang, L. Liu, and Z. Liu, "An interpretable and expandable deep learning diagnostic system for multiple ocular diseases: Qualitative study," *Journal of Medical Internet Research*, vol. 20, no. 11, 2018.
- [93] C. Xu, X. Zhu, W. He, Y. Lu, X. He, Z. Shang, J. Wu, K. Zhang, Y. Zhang, X. Rong *et al.*, "Fully deep learning for slit-lamp photo based nuclear cataract grading," in *International Conference on Medical Image Computing and Computer-Assisted Intervention*. Springer, 2019, pp. 513–521.
- [94] D. S. J. Ting, M. Ang, J. S. Mehta, and D. S. W. Ting, "Artificial intelligence-assisted telemedicine platform for cataract screening and management: a potential model of care for global eye health," 2019.
- [95] X. Wu, Y. Huang, Z. Liu, W. Lai, E. Long, K. Zhang, J. Jiang, D. Lin, K. Chen, T. Yu *et al.*, "Universal artificial intelligence platform for collaborative management of cataracts," *British Journal of Ophthalmology*, vol. 103, no. 11, pp. 1553–1560, 2019.
- [96] S. Hu, X. Wang, H. Wu, X. Luan, P. Qi, Y. Lin, X. He, and W. He, "Unified diagnosis framework for automated nuclear cataract grading based on smartphone slit-lamp images," *IEEE Access*, vol. 8, pp. 174 169–174 178, 2020.
- [97] J. Jiang, L. Wang, H. Fu, E. Long, Y. Sun, R. Li, Z. Li, M. Zhu, Z. Liu, J. Chen *et al.*, "Automatic classification of heterogeneous slit-illumination images using an ensemble of cost-sensitive convolutional neural networks," *Annals of Translational Medicine*, vol. 9, no. 7, 2021.
- [98] H. R. Tawfik, R. A. Birry, and A. A. Saad, "Early recognition and grading of cataract using a combined log gabor/discrete wavelet transform with ann and svm," *International Journal of Computer and Information Engineering*, vol. 12, no. 12, pp. 1038–1043, 2018.



- [99] L. Zhang, J. Li, H. Han, B. Liu, J. Yang, Q. Wang *et al.*, "Automatic cataract detection and grading using deep convolutional neural network," in *2017 IEEE 14th International Conference on Networking, Sensing and Control (ICNSC)*. IEEE, 2017, pp. 60–65.
- [100] Y. Dong, Q. Zhang, Z. Qiao, and J.-J. Yang, "Classification of cataract fundus image based on deep learning," in *2017 IEEE International Conference on Imaging Systems and Techniques (IST)*. IEEE, 2017, pp. 1–5.
- [101] X. Xu, L. Zhang, J. Li, Y. Guan, and L. Zhang, "A hybrid global-local representation cnn model for automatic cataract grading," *IEEE journal of biomedical and health informatics*, 2019.
- [102] Linglin Zhang, Jianqiang Li, i Zhang, He Han, Bo Liu, J. Yang, and Qing Wang, "Automatic cataract detection and grading using deep convolutional neural network," in *2017 IEEE 14th International Conference on Networking, Sensing and Control (ICNSC)*, 2017, pp. 60–65.
- [103] X. Zhang, Z. Xiao, H. Risa, W. Chen, J. Yuan, J. Fang, Y. Hu, and J. Liu, "A novel deep learning method for nuclear cataract classification based on anterior segment optical coherence tomography images," in *IEEE SMC*, 2020.
- [104] C. Szegedy, W. Liu, Y. Jia, P. Sermanet, S. Reed, D. Anguelov, D. Erhan, V. Vanhoucke, and A. Rabinovich, "Going deeper with convolutions," in *Proceedings of the IEEE conference on computer vision and pattern recognition*, 2015, pp. 1–9.
- [105] A. Krizhevsky, I. Sutskever, and G. E. Hinton, "Imagenet classification with deep convolutional neural networks," in *Advances in neural information processing systems*, 2012, pp. 1097–1105.
- [106] H. Chen, Q. Dou, D. Ni, J.-Z. Cheng, J. Qin, S. Li, and P.-A. Heng, "Automatic fetal ultrasound standard plane detection using knowledge transferred recurrent neural networks," in *International Conference on Medical Image Computing and Computer-Assisted Intervention*. Springer, 2015, pp. 507–514.
- [107] H. Fu, Y. Xu, S. Lin, D. W. K. Wong, and J. Liu, "Deepvessel: Retinal vessel segmentation via deep learning and conditional random field," in *International conference on medical image computing and computer-assisted intervention*. Springer, 2016, pp. 132–139.
- [108] M. D. Abràmoff, Y. Lou, A. Erginay, W. Clarida, R. Amelon, J. C. Folk, and M. Niemeijer, "Improved automated detection of diabetic retinopathy on a publicly available dataset through integration of deep learning," *Investigative ophthalmology & visual science*, vol. 57, no. 13, pp. 5200–5206, 2016.
- [109] G. Litjens, T. Kooi, B. E. Bejnordi, A. A. A. Setio, F. Ciompi, M. Ghafoorian, J. A. Van Der Laak, B. Van Ginneken, and C. I. Sánchez, "A survey on deep learning in medical image analysis," *Medical image analysis*, vol. 42, pp. 60–88, 2017.
- [110] A. Mansoor, J. J. Cerrolaza, R. Idrees, E. Biggs, M. A. Alsharid, R. A. Avery, and M. G. Linguraru, "Deep learning guided partitioned shape model for anterior visual pathway segmentation," *IEEE transactions on medical imaging*, vol. 35, no. 8, pp. 1856–1865, 2016.
- [111] S. Xie, R. Girshick, P. Dollár, Z. Tu, and K. He, "Aggregated residual transformations for deep neural networks," in *Proceedings of the IEEE conference on computer vision and pattern recognition*, 2017, pp. 1492–1500.
- [112] C. Szegedy, V. Vanhoucke, S. Ioffe, J. Shlens, and Z. Wojna, "Rethinking the inception architecture for computer vision," in *Proceedings of the IEEE conference on computer vision and pattern recognition*, 2016, pp. 2818–2826.
- [113] G. Huang, Z. Liu, L. Van Der Maaten, and K. Q. Weinberger, "Densely connected convolutional networks," in *Proceedings of the IEEE conference on computer vision and pattern recognition*, 2017, pp. 4700–4708.
- [114] X. Zhang, X. Zhou, M. Lin, and J. Sun, "Shufflenet: An extremely efficient convolutional neural network for mobile devices," in *Proceedings of the IEEE Conference on Computer Vision and Pattern Recognition*, 2018, pp. 6848–6856.
- [115] P. S. Grewal, F. Oloumi, U. Rubin, and M. T. Tennant, "Deep learning in ophthalmology: a review," *Canadian Journal of Ophthalmology*, vol. 53, no. 4, pp. 309–313, 2018.
- [116] L. Deng, P. Jiao, J. Pei, Z. Wu, and G. Li, "Gxnet: Training deep neural networks with ternary weights and activations without full-precision memory under a unified discretization framework," *Neural Networks*, vol. 100, pp. 49–58, 2018.
- [117] P. Yin, M. Tan, H. Min, Y. Xu, G. Xu, Q. Wu, Y. Tong, H. Risa, and J. Liu, "Automatic segmentation of cortex and nucleus in anterior segment oct images," in *Computational Pathology and Ophthalmic Medical Image Analysis*. Springer, 2018, pp. 269–276.
- [118] S. Zhang, Y. Yan, P. Yin, Z. Qiu, W. Zhao, G. Cao, W. Chen, J. Yuan, R. Higashita, Q. Wu *et al.*, "Guided m-net for high-resolution biomedical image segmentation with weak boundaries," in *International Workshop on Ophthalmic Medical Image Analysis*. Springer, 2019, pp. 43–51.
- [119] G. Cao, W. Zhao, R. Higashita, J. Liu, W. Chen, J. Yuan, Y. Zhang, and M. Yang, "An efficient lens structures segmentation method on as-oct images," in *2020 42nd Annual International Conference of the IEEE Engineering in Medicine & Biology Society (EMBC)*. IEEE, 2020, pp. 1646–1649.
- [120] J. Cong and B. Xiao, "Minimizing computation in convolutional neural networks," 2014.
- [121] A. W. P. Foong, S.-M. Saw, J.-L. Loo, S. Shen, S.-C. Loon, M. Rosman, T. Aung, D. T. H. Tan, E. S. Tai, and T. Y. Wong, "Rationale and methodology for a population-based study of eye diseases in malay people: The singapore malay eye study (simes)," *Ophthalmic Epidemiology*, vol. 14, no. 1, pp. 25–35, 2007. [Online]. Available: <https://doi.org/10.1080/09286580600878844>
- [122] S. Resnikoff, V. C. Lansingh, L. Washburn, W. Felch, T.-M. Gauthier, H. R. Taylor, K. Eckert, D. Parke, and P. Wiedemann, "Estimated number of ophthalmologists worldwide (international council of ophthalmology update): will we meet the needs?" *British Journal of Ophthalmology*, vol. 104, no. 4, pp. 588–592, 2020. [Online]. Available: <https://bjoo.bmj.com/content/104/4/588>
- [123] S. Resnikoff, W. Felch, T.-M. Gauthier, and B. Spivey, "The number of ophthalmologists in practice and training worldwide: a growing gap despite more than 200 000 practitioners," *British Journal of Ophthalmology*, vol. 96, no. 6, pp. 783–787, 2012.
- [124] S. Ravi and H. Larochelle, "Optimization as a model for few-shot learning," 2016.
- [125] N. Gira, M. Crucianu, and N. Boujemaa, "Unsupervised and semi-supervised clustering: a brief survey," *A review of machine learning techniques for processing multimedia content*, vol. 1, pp. 9–16, 2004.
- [126] S. Fogel, H. Averbuch-Elor, D. Cohen-Or, and J. Goldberger, "Clustering-driven deep embedding with pairwise constraints," *IEEE computer graphics and applications*, vol. 39, no. 4, pp. 16–27, 2019.
- [127] X. Guo, X. Liu, E. Zhu, and J. Yin, "Deep clustering with convolutional autoencoders," in *International Conference on Neural Information Processing*. Springer, 2017, pp. 373–382.
- [128] Y.-C. Hsu and Z. Kira, "Neural network-based clustering using pairwise constraints," *arXiv preprint arXiv:1511.06321*, 2015.
- [129] B. Ramamurthy and K. Chandran, "Content based image retrieval for medical images using canny edge detection algorithm," *International Journal of Computer Applications*, vol. 17, no. 6, pp. 32–37, 2011.
- [130] J. Sivakamasundari, G. Kavitha, V. Natarajan, and S. Ramakrishnan, "Proposal of a content based retinal image retrieval system using kirsch template based edge detection," in *2014 International Conference on Informatics, Electronics & Vision (ICIEV)*. IEEE, 2014, pp. 1–5.
- [131] Y. F. Fathabad and M. Balafar, "Content based image retrieval for medical images," *International Journal on Technical and Physical Problems of Engineering (IJTPE)*, no. 12, pp. 177–182, 2012.
- [132] D. Lin, J. Chen, Z. Lin, X. Li, K. Zhang, X. Wu, Z. Liu, J. Huang, J. Li, and Y. a. Zhu, "A practical model for the identification of congenital cataracts using machine learning," *EBioMedicine*, vol. 51, 2020.
- [133] M. Yang, J.-J. Yang, Q. Zhang, Y. Niu, and J. Li, "Classification of retinal image for automatic cataract detection," in *2013 IEEE 15th International Conference on e-Health Networking, Applications and Services (Healthcom 2013)*. IEEE, 2013, pp. 674–679.
- [134] M. J. Cardoso, T. Arbel, G. Carneiro, T. Syeda-Mahmood, J. M. R. Tavares, M. Moradi, A. Bradley, H. Greenspan, J. P. Papa, A. Madabhushi *et al.*, "Deep learning in medical image analysis and multimodal learning for clinical decision support," 2017.
- [135] J. Ma, Z. Zhao, J. Chen, A. Li, L. Hong, and E. Chi, "Snr: Sub-network routing for flexible parameter sharing in multi-task learning," *Proceedings of the AAAI Conference on Artificial Intelligence*, vol. 33, pp. 216–223, 07 2019.
- [136] Z. Guo, X. Li, H. Huang, N. Guo, and Q. Li, "Deep learning-based image segmentation on multimodal medical imaging," *IEEE Transactions on Radiation and Plasma Medical Sciences*, vol. 3, no. 2, pp. 162–169, March 2019.
- [137] B. Cheng, M. Liu, H.-I. Suk, D. Shen, D. Zhang, A. D. N. Initiative *et al.*, "Multimodal manifold-regularized transfer learning for mci conversion prediction," *Brain imaging and behavior*, vol. 9, no. 4, pp. 913–926, 2015.
- [138] S.-F. Mohammadi, M. Sabbaghi, Z. Hadi, H. Hashemi, S. Alizadeh, M. Majidi, F. Taei *et al.*, "Using artificial intelligence to predict the risk

- for posterior capsule opacification after phacoemulsification,” *Journal of Cataract & Refractive Surgery*, vol. 38, no. 3, pp. 403–408, 2012.
- [139] D. Lin, J. Chen, Z. Lin, X. Li, K. Zhang, X. Wu, Z. Liu, J. Huang, J. Li, Y. Zhu *et al.*, “A practical model for the identification of congenital cataracts using machine learning,” *EBioMedicine*, vol. 51, p. 102621, 2020.
- [140] C. Guo, G. Pleiss, Y. Sun, and K. Q. Weinberger, “On calibration of modern neural networks,” in *Proceedings of the 34th International Conference on Machine Learning-Volume 70*. JMLR. org, 2017, pp. 1321–1330.
- [141] R. Müller, S. Kornblith, and G. Hinton, “When does label smoothing help?” *arXiv preprint arXiv:1906.02629*, 2019.
- [142] B. Zhou, A. Khosla, A. Lapedriza, A. Oliva, and A. Torralba, “Learning deep features for discriminative localization,” in *Proceedings of the IEEE conference on computer vision and pattern recognition*, 2016, pp. 2921–2929.
- [143] R. R. Selvaraju, M. Cogswell, A. Das, R. Vedantam, D. Parikh, and D. Batra, “Grad-cam: Visual explanations from deep networks via gradient-based localization,” in *Proceedings of the IEEE international conference on computer vision*, 2017, pp. 618–626.
- [144] R. Guidotti, A. Monreale, S. Ruggieri, F. Turini, F. Giannotti, and D. Pedreschi, “A survey of methods for explaining black box models,” *ACM computing surveys (CSUR)*, vol. 51, no. 5, pp. 1–42, 2018.
- [145] J. Lu, C. Xiong, D. Parikh, and R. Socher, “Knowing when to look: Adaptive attention via a visual sentinel for image captioning,” in *Proceedings of the IEEE conference on computer vision and pattern recognition*, 2017, pp. 375–383.
- [146] S. Kornblith, M. Norouzi, H. Lee, and G. Hinton, “Similarity of neural network representations revisited,” 2019.
- [147] R. Supriyanti and Y. Ramadhani, “The achievement of various shapes of specular reflections for cataract screening system based on digital images,” in *International Conference on Biomedical Engineering and Technology (ICBET)*. Kuala Lumpur, Malaysia, 2011.
- [148] —, “Consideration of iris characteristic for improving cataract screening techniques based on digital image,” in *2nd International Conference on Biomedical Engineering and Technology IPCBEE*, vol. 34. IACSIT Press, 2012.
- [149] J. Rana and S. M. Galib, “Cataract detection using smartphone,” in *2017 3rd International Conference on Electrical Information and Communication Technology (EICT)*. IEEE, 2017, pp. 1–4.
- [150] Y. Cheng, D. Wang, P. Zhou, and T. Zhang, “A survey of model compression and acceleration for deep neural networks,” *arXiv preprint arXiv:1710.09282*, 2017.
- [151] Y. Jiang, S. Wang, V. Valls, B. J. Ko, W.-H. Lee, K. K. Leung, and L. Tassioulas, “Model pruning enables efficient federated learning on edge devices,” *arXiv preprint arXiv:1909.12326*, 2019.
- [152] Y. He, X. Zhang, and J. Sun, “Channel pruning for accelerating very deep neural networks,” in *Proceedings of the IEEE International Conference on Computer Vision*, 2017, pp. 1389–1397.