

# ReXGroundingCT: A 3D Chest CT Dataset for Segmentation of Findings from Free-Text Reports

Mohammed Baharoon, BS<sup>\*,1</sup>, Luyang Luo, PhD<sup>\*,1</sup>, Michael Moritz, MD<sup>2,3</sup>, Abhinav Kumar, MS<sup>5</sup>, Sung Eun Kim, MD<sup>1,6</sup>, Xiaoman Zhang, PhD<sup>1</sup>, Miao Zhu, MD<sup>4</sup>, Mahmoud Hussain Alabbad, MBBS<sup>7,8</sup>, Maha Sbayel Alhazmi, MBBS<sup>7,8</sup>, Neel P. Mistry, MD<sup>9</sup>, Kent Ryan Kleinschmidt, BS<sup>3</sup>, Brady Chrisler, BS<sup>3</sup>, Sathvik Suryadevara, BS<sup>3</sup>, Sri Sai Dinesh Jaliparthi, BS<sup>3</sup>, Noah Michael Prudlo, BS<sup>3</sup>, Mark David Marino, BS<sup>3</sup>, Jeremy Palacio, BS<sup>3</sup>, Rithvik Akula, BS<sup>3</sup>, Hong-Yu Zhou, PhD<sup>1</sup>, Ibrahim Ethem Hamamci, MD<sup>10</sup>, Scott J. Adams, MD, PhD<sup>9</sup>, Hassan Rayhan AlOmaish, MBBS<sup>7,8</sup>, and Pranav Rajpurkar, PhD<sup>1</sup>

<sup>1</sup>Department of Biomedical Informatics, Harvard Medical School, Boston, MA

<sup>2</sup>SSM Health, St. Louis, MO

<sup>3</sup>Saint Louis University School of Medicine, St. Louis, MO

<sup>4</sup>Brigham and Women's Hospital, Boston, MA

<sup>5</sup>Icahn School of Medicine at Mount Sinai, New York, NY

<sup>6</sup>National Strategic Technology Research Institute, Seoul National University Hospital, South Korea

<sup>7</sup>Chest Radiology Division, Medical Imaging Department, King Abdullah Specialized Children's Hospital, Riyadh, Saudi Arabia

<sup>8</sup>King Abdulaziz Medical City, Ministry of National Guard Health Affairs, Riyadh, Saudi Arabia

<sup>9</sup>Department of Medical Imaging, Royal University Hospital, Saskatoon, SK, Canada

<sup>10</sup>University of Zurich, Switzerland

## Abstract

We present ReXGroundingCT, the first publicly available dataset to link free-text radiology findings with pixel-level segmentations in 3D chest CT scans that is manually annotated. While prior datasets have relied on structured labels or predefined categories, ReXGroundingCT captures the full expressiveness of clinical language represented in free text and grounds it to spatially localized 3D segmentation annotations in volumetric imaging. This addresses a critical gap in medical AI: the ability to connect complex, descriptive text, such as “3 mm nodule in the left lower lobe”, to its precise anatomical location in three-dimensional space, a capability essential for grounded radiology report generation systems. The dataset comprises 3,142 non-contrast chest CT scans paired with standardized radiology reports from the CT-RATE dataset. Using a systematic three-stage pipeline, GPT-4 was used to extract positive lung and pleural findings, which were then manually segmented by expert annotators. A total of 8,028 findings across 16,301 entities were annotated, with quality control performed by board-certified radiologists. Approximately 79% of findings are focal abnormalities, while 21% are non-focal. The training set includes up to three representative segmentations per finding, while the validation and test sets contain exhaustive labels for each finding entity. ReXGroundingCT establishes a new benchmark for developing and evaluating sentence-level grounding and free-text medical segmentation models in chest CT. The dataset can be accessed at <https://huggingface.co/datasets/rajpurkarlab/ReXGroundingCT>.

<sup>\*</sup>Equal contribution.

Contact Email: MohammedSalimAB@outlook.com

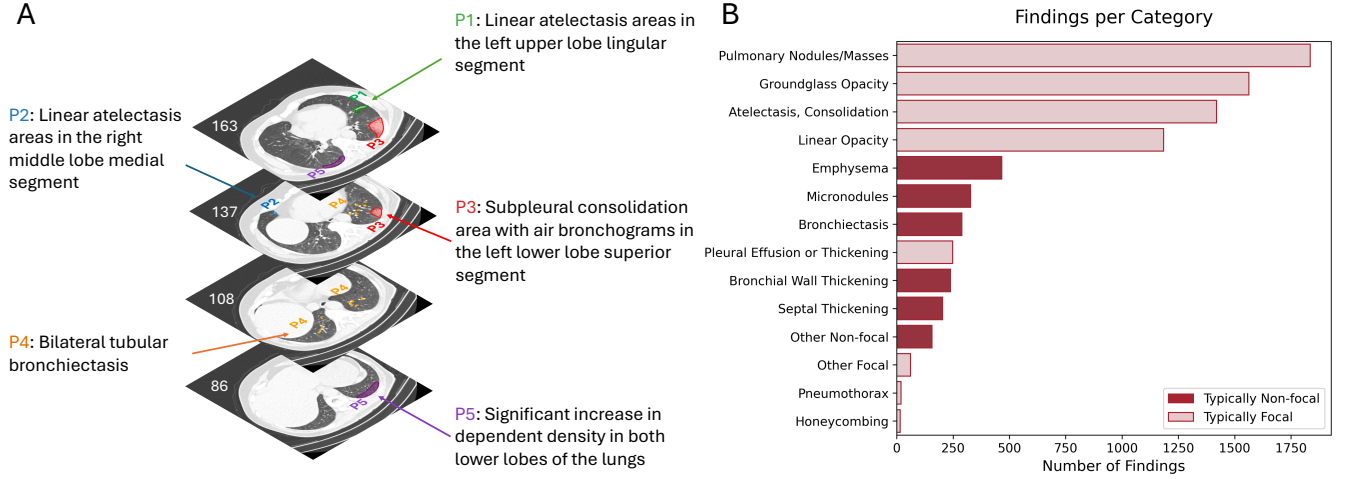


Figure 1: (A) Examples of mapping narrative free-text findings from a radiology report to precise 3D spatial locations in a chest CT scan. Five representative findings illustrate various anatomical sites and patterns of disease. Numbers indicate CT slice locations where the findings are visualized. (B) Distribution of findings per category across the dataset, grouped by typical pattern (non-focal vs. focal).

## 1 Introduction

Artificial intelligence (AI) is increasingly transforming healthcare, driving the development of systems that can interpret complex medical images and assist clinical decision-making [19]. However, deployment in clinical practice depends not only on technical performance, but also on generating outputs that are explainable and verifiable [18, 1]. One emerging frontier is grounded radiology report generation (GRRG), which aims to produce detailed textual descriptions of imaging findings paired with precise spatial localizations in the imaging volume, linking language and anatomy in a clinically meaningful way [6, 9, 17, 11].

A central challenge for GRRG lies in bridging the gap between unstructured, free-text radiology reports and precise three-dimensional localization of findings within chest CT scans. Translating these narrative descriptions into spatially grounded labels remains largely unsolved. Existing chest CT datasets provide categorical labels or lesion masks but cannot represent the rich variability of free-text language [10, 20, 5].

We introduce **ReXGroundingCT**, the first publicly available manually annotated dataset connecting free-text radiology findings to precise 3D spatial localizations in chest CT imaging. Unlike previous data sets focused on predefined disease categories, ReXGroundingCT captures a diverse descriptive language and pairs it with detailed 3D segmentation masks. The dataset was developed via a multi-stage pipeline involving report standardization, finding extraction and categorization, and pixel-level annotation of CT scans by trained annotators and board-certified radiologists. An example of a data point from ReXGroundingCT is shown in Figure 1, A.

## 2 Methods

### 2.1 Source Data

ReXGroundingCT is built upon CT-RATE, a publicly available dataset pairing non-contrast 3D chest CT volumes with corresponding radiology reports [13]. CT-RATE includes 25,692 chest CT studies, reconstructed into 50,188 volumes, totaling over 14.3 million axial slices, acquired between May 2015 and January 2023 at Istanbul Medipol University Mega Hospital in Turkey. The dataset spans 21,304 unique patients with an average age of 48.8 years and a sex distribution of 41.6% female and 58.4% male.

Radiology reports in CT-RATE are structured into four sections: clinical information, technique, findings, and impression. Originally written in Turkish, reports were machine-translated into English and corrected by bilingual medical students for clarity and consistency. Extensive anonymization was performed to remove personal identifiers from both the imaging data and the reports.

For ReXGroundingCT, we curated 3,142 chest CT volumes from CT-RATE, selected sequentially in groups by increasing CT-RATE ID. Because IDs are randomly assigned, this yields a representative random sample. Each selected volume retains its English report and metadata, including patient demographics and scan parameters.

### 2.2 Report Rewriting

A qualitative review by a board-certified radiologist found that reports in the CT-RATE dataset often contained non-standard terminology and inconsistent phrasing due to translation artifacts and varied reporting styles. To address this, we developed a report rewriting pipeline

using GPT-4 [2] to produce standardized reports with terminology and phrasing aligned with conventions typical of U.S. radiology practice.

The model was instructed to correct non-standard terminology to align with conventions typical of American radiology practice and to improve grammatical clarity, while preserving all clinical details, measurements, and anatomical references. For example, terms such as “millimetric” were rewritten as “subcentimeter,” “pleuroparenchymal sequelae” was simplified to “scarring” or “fibrosis,” and phrases like “no space-occupying lesion” were replaced with “no lesion.” Irrelevant statements that were not related to clinical interpretation were removed to improve the conciseness and clarity of the report.

Quality control was performed through manual review by a board-certified radiologist. Over 50 reports were qualitatively reviewed and rated on a binary acceptable versus not acceptable basis, with all 50 reports deemed acceptable by the radiologist. The rewriting prompt used in this process was developed through a multistep design in collaboration with the radiologist to ensure high fidelity to clinical meaning and reporting standards. These standardized reports formed the basis for subsequent abnormality extraction, categorization, and annotation in ReXGroundingCT.

### 2.3 Abnormality Extraction and Categorization

Following the rewriting of CT-RATE reports, we implemented a two-stage pipeline to extract and categorize abnormalities from each standardized radiology report.

For abnormality extraction, we prompted GPT-4 to systematically analyze the rewritten Findings and Impressions sections, isolating distinct anatomical observations, whether normal or abnormal. The model was instructed to split sentences describing multiple findings into separate entries and to consolidate information spread across multiple sentences into unified, detailed findings. Extracted phrases included details such as lesion size, morphology, anatomical location, and any references to prior imaging studies indicating stability or change over time. The extraction process explicitly excluded interpretive language, diagnostic speculation, and clinical recommendations, focusing solely on observable imaging features. Measurements were normalized to a consistent format, rounding millimeter values to whole numbers and limiting centimeter values to one decimal place. The model’s output listed each extracted finding alongside its abnormality status and any indication of reference to prior imaging.

After extraction, each finding was categorized using GPT-4o-mini into a two-level hierarchical schema comprising 12 parent categories and 61 subcategories, shown in Figure D, developed in consultation with a board-certified radiologist to reflect a comprehensive spectrum of chest CT findings encountered in clinical practice. This schema

accommodates both focal abnormalities, such as nodules or localized consolidations, and non-focal patterns, including diffuse interstitial changes and widespread emphysema, as well as a broad range of non-pulmonary findings. Categorization was performed using GPT-4o-mini, which received the text of each extracted phrase and assigned it to the appropriate subcategory.

To evaluate the accuracy of the extraction and categorization pipeline, we conducted a manual review of 100 randomly sampled reports, assessed by a board-certified radiologist. Each extracted finding was evaluated for (1) missing descriptors—defined as omissions of essential details such as anatomical location, shape, or measurement—(2) false positives, and (3) false negatives. No false positive extractions were observed, and the rates of false negatives were low: 0.05 in the rephrasing step and 0.01 in the extraction step. Descriptor omissions occurred at rates of 0.14 in the rephrasing step and 0.13 in the extraction step, indicating strong fidelity between the extracted findings and the original report content. For categorization, GPT-4o-mini achieved a precision and recall of 0.99 for lung and pleural findings across the full 12-category ontology. In a subset of 100 findings from categories 1 and 2 (Figure D), GPT-4o-mini attained an F1 score of 0.92 for subcategory classification. An example of report extraction and categorization pipeline is illustrated in Figure 2.

### 2.4 Annotation

All annotations for ReXGroundingCT were performed using a HIPAA-compliant, cloud-based medical imaging annotation platform. Figure 3 illustrates the full data construction pipeline, while Figure 4 shows the interface of the platform.

**Annotation Protocols.** The training set included 2,992 chest CT cases, annotated in two different protocols, with quality checks done in both. Using protocol 1, 1,400 cases were annotated by professional annotators, with radiologists refining the cases before accepting them to ensure accuracy. Most annotators have over 1.5 years of medical annotation experience. Radiologists either accepted the segmentations, corrected them directly, or returned them to the annotators for revision when significant discrepancies were identified.

Using the second protocol 2, 1,592 cases were annotated by medical students that are supervised by radiologists. The students underwent dedicated training for this annotation task, during which their performance was monitored and assessed. Incorrect annotations were corrected by supervising radiologists until the students demonstrated sufficient proficiency to perform the annotations independently.

The test and validation sets contain 100 and 50 cases, respectively, and were annotated exclusively by board-certified radiologists, ensuring high-quality and reliable evaluations.

## Findings

The diameter of the ascending aorta was 38 mm and increased. No occlusive pathology was detected in the trachea and both main bronchi. In the left lung lower lobe superior segment, there is a consolidation area in the subpleural area in which air bronchograms are observed. There is bilateral tubular bronchiectasis. Linear atelectasis areas are observed in the right lung middle lobe medial segment. There is a significant increase in dependent density in both lung lower lobes on the right. No pathological wall thickness increase was observed in the esophagus within the sections. Sliding type minimal hiatal hernia is observed at the esophagogastric junction.

## Rephrasing and Extraction

Finding	Code	Abnormal	Prior
Increased diameter of the ascending aorta, 38 mm	H0	Yes	No
No occlusive pathology in the trachea and both main bronchi	L0	No	No
Subpleural consolidation area with air bronchograms in the left lower lobe superior segment	L1	Yes	No
Bilateral tubular bronchiectasis	L2	Yes	No
Linear atelectasis areas in the right middle lobe medial segment	L3	Yes	No
Significant increase in dependent density in both lower lobes of the lungs	L4	Yes	No
No pathological wall thickening in the esophagus	M0	No	No
Sliding type minimal hiatal hernia at the esophagogastric junction	M1	No	No

## Categorization

Lung Finding	Category
Subpleural consolidation area with air bronchograms in the left lower lobe superior segment	Atelectasis/Consolidation
Bilateral tubular bronchiectasis	Bronchiectasis
Linear atelectasis areas in the right middle lobe medial segment	Linear Opacity
Significant increase in dependent density in both lower lobes of the lungs	Atelectasis/Consolidation

Figure 2: Illustration of the structured pipeline for converting narrative radiology reports into standardized reports. The example shows how a free-text report is parsed into discrete findings, each assessed for abnormality and prior reference, followed by categorization into defined ontology classes. Findings that have a code that starts with "H" refer to "Heart/Vessels" findings, where "L" refer to "Lungs/Airways/Pleura" findings, and "M" refers to "Mediastinum/Hila".

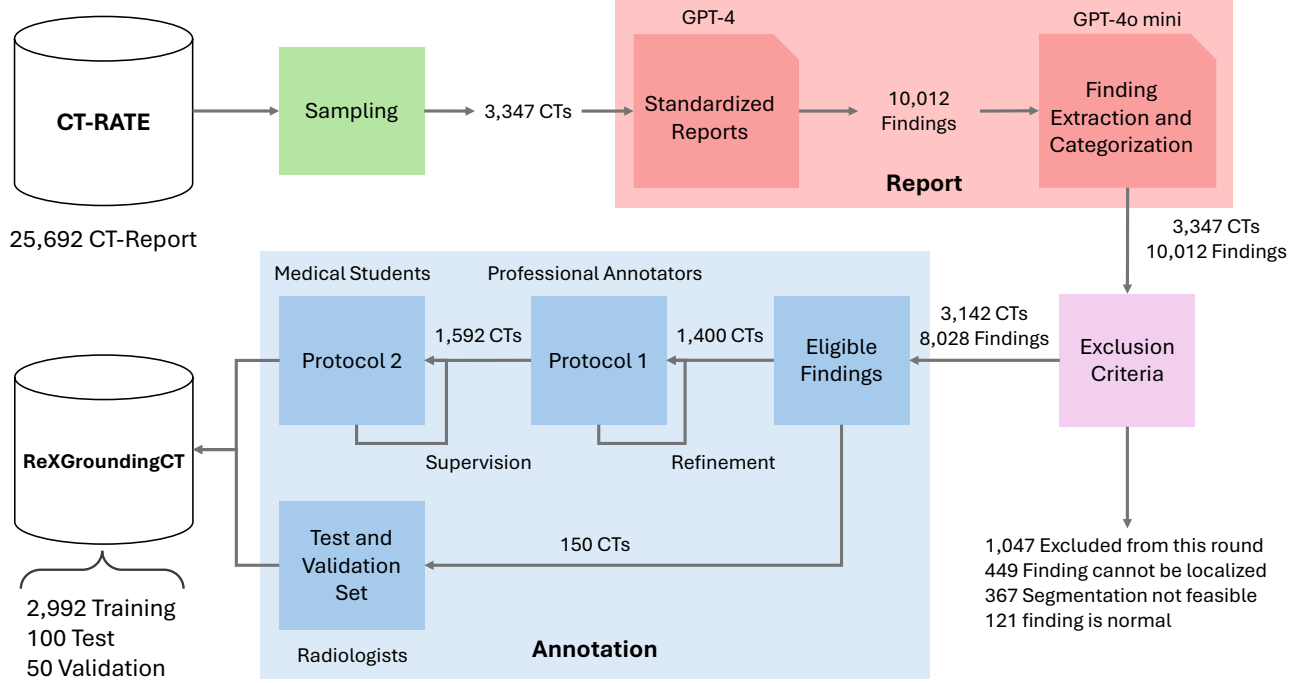


Figure 3: ReXGroundingCT dataset construction pipeline. The training set was annotated with a maximum of three representative instances per finding to manage workload, while the validation and test sets were annotated exhaustively, with all visible instances segmented to provide full ground truth. In protocol 1, all cases were reviewed and refined by board-certified radiologists, ensuring high-quality segmentations. In protocol 2, medical students received structured training and were supervised by senior radiologists, who provided corrections until the students demonstrated sufficient proficiency to annotate independently. The test and validation sets were done exclusively by board-certified radiologists

**Entity Protocol.** The training set followed a different annotation protocol than the validation and test sets. Annotators were instructed to segment no more than three representative instances of a given entity (e.g., up to three nodules), even if more were present. This strategy was used to manage annotation workload. In contrast, the validation and test sets required exhaustive labeling, where annotators segmented all visible instances of each finding to provide complete ground truth for evaluation.

**Quality control.** Annotation proceeded in two stages: quality control and subsequent segmentation of findings. Across the annotated CT scans, a total of 10,012 distinct findings were initially identified for potential segmentation. During quality control, individual findings were excluded under several specific criteria. A total of 1,047 findings were excluded because they fell outside the scope for this dataset, as only lung and pleura findings were annotated; exclusions in this category included findings such as vascular calcifications or abnormalities in other thoracic or upper abdominal structures. Another 449 findings were excluded because they could not be localized in the CT scan—for example, when a report described a small nodule at a specific location that was not visible to the annotator. An additional 367 findings were excluded because segmentation or bounding was not feasible due to their diffuse nature, including patterns like “decreased aeration in the lung” or extensive “mosaic patterns of attenuation,” which would have required segmenting large portions or the entirety of the lung volume. Lastly, 121 findings were excluded because they represented normal anatomical structures or benign variations, such as subcentimeter lymph nodes considered non-pathological. After applying these exclusion criteria, 8,028 findings remained in the dataset and were included for segmentation and subsequent modeling.

In the segmentation stage, annotators delineated each selected finding within the 3D CT volumes using pixel-level masks. A suite of tools—including brush, polygon, and smart region-growing features—was available to support precise and efficient segmentation of abnormalities. The annotation interface also allowed real-time navigation across slices and adjustment of window levels to enhance visibility during labeling.

### 3 ReXGroundingCT

The resulting ReXGroundingCT dataset comprises 3,142 chest CT scans and 8,028 segmented findings, representing a diverse range of pulmonary and pleural abnormalities. The average age of patients in the dataset is  $42.08 \pm 14.52$  years, with a sex distribution of 55.9% male and 44.1% female. Scans included in ReXGroundingCT were acquired between February 2016 and November 2022, reflecting a broad clinical sampling period across varied patient populations and imaging conditions. All scans are non-contrast chest CT studies, reconstructed with

slice thicknesses ranging from 0.50 mm to 5.00 mm, and axial pixel spacing between 0.30 mm and 0.98 mm. Most volumes have matrix sizes of  $512 \times 512$  (92.6%), though higher resolutions such as  $768 \times 768$  (7.2%) and  $1024 \times 1024$  (0.2%) are also present. The number of slices per volume varies from 104 to 1005, with a mean of approximately 351 slices.

In total, the dataset contains 8,028 segmented findings, with 16,301 separate entities, distributed across both focal and non-focal abnormalities. Approximately 79% of findings are focal lesions, such as nodules or localized consolidations, while the remaining 21% represent diffuse or infiltrative patterns. Each finding is associated with a precise 3D segmentation mask, enabling detailed spatial analysis. ReXGroundingCT’s findings span 14 categories (Figure 1, B), of which 8 are focal and 6 are non-focal, encompassing diverse pulmonary and pleural abnormalities. The most common focal category is “Pulmonary Nodules/Masses”, accounting for 28.9% of focal findings, while the most common non-focal category is “Emphysema”, representing 27.7% of non-focal findings.

In the training set, each finding contains an average of 1.95 entities due to the annotation protocol limiting segmentation to at most three instances per finding. In contrast, scans in the test and validation sets combined contain an average of 3.80 finding entities, reflecting a more comprehensive annotation of all visible abnormalities (see Figure A.1).

## 4 Limitations

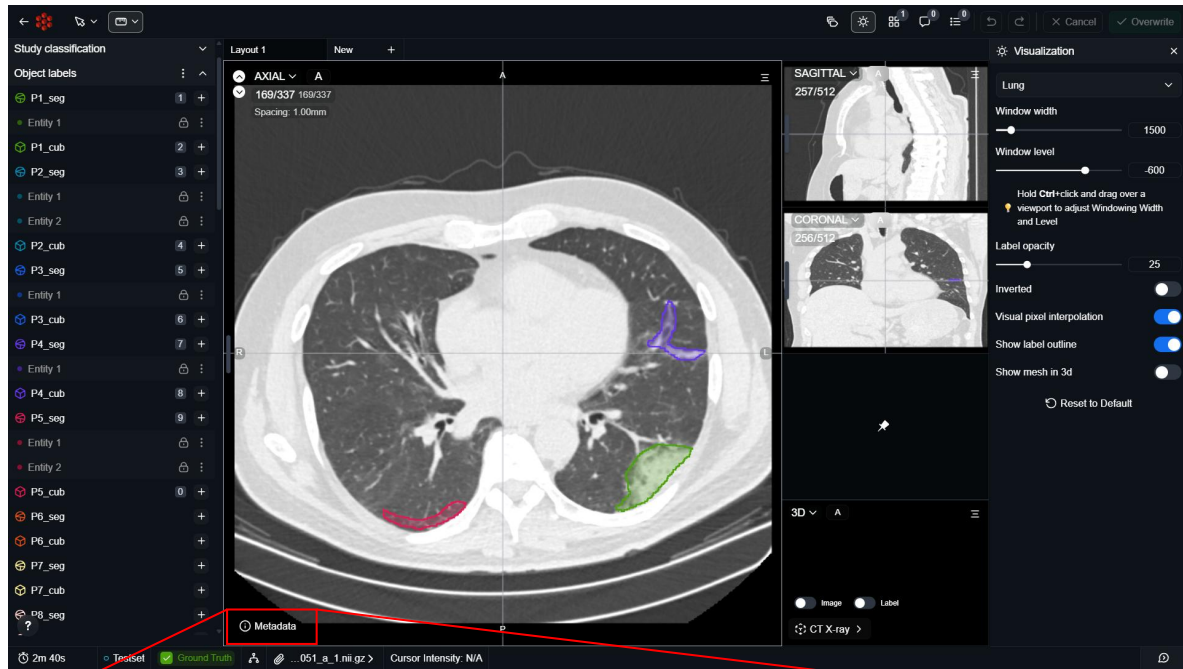
While ReXGroundingCT represents a significant advance in linking free-text radiology findings to 3D segmentations, several limitations should be considered.

First, annotations in the training set were performed by professional annotators and medical students, rather than exclusively by board-certified radiologists. This introduces potential variability in annotation quality. However, to mitigate this issue, all annotations underwent structured quality control processes. In Protocol 1, radiologists reviewed and directly corrected annotations or returned them for revision. In Protocol 2, medical students were trained under the supervision of senior radiologists, who monitored their progress and corrected all errors until the students demonstrated sufficient proficiency.

Second, in the training set, annotators were instructed to segment no more than three representative instances per finding. This partial labeling strategy, while essential for managing the annotation workload across thousands of volumes, limits the completeness of spatial annotations. Nonetheless, this limitation can be addressed in model development using weakly supervised or semi-supervised learning techniques that can leverage incomplete annotations to infer full spatial representations [21, 12].

Finally, the dataset focuses exclusively on lung and

A



B

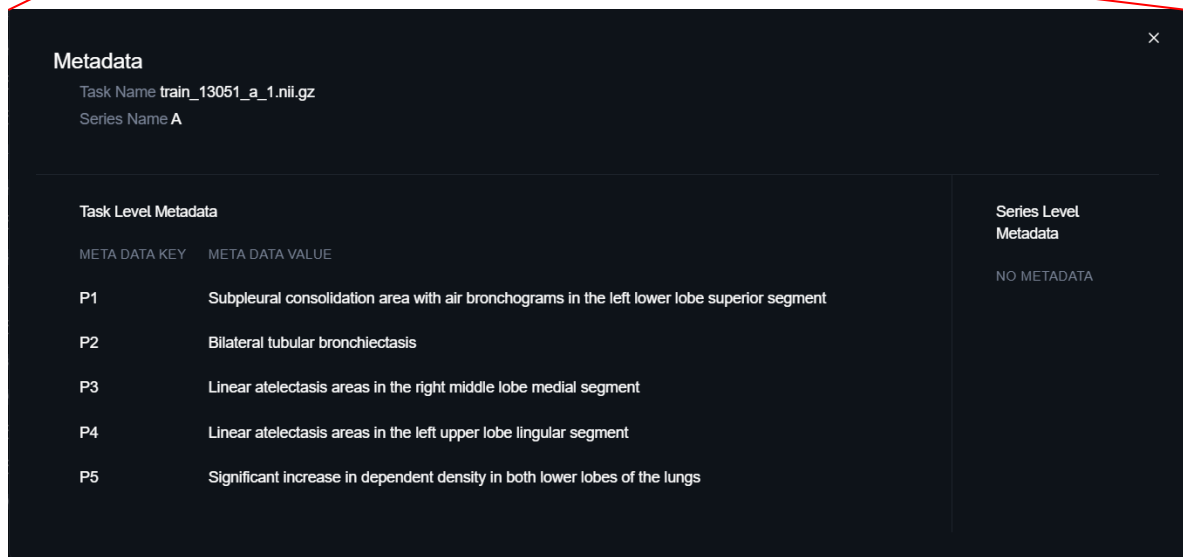


Figure 4: (A) A 3D chest CT scan displayed within the annotation platform, showing multiple pixel-level segmentations corresponding to individual findings (e.g., P1–P5), each color-coded and labeled in the left panel. (B) Associated metadata panel, showing free-text descriptions for each annotated finding. Annotators used this interface to review CT volumes and perform labeling of abnormalities.

pleural findings, with non-pulmonary findings excluded during quality control. This restricts the dataset’s applicability to other thoracic or abdominal abnormalities. Expanding the annotation scope to include these findings could improve the dataset’s generalizability for comprehensive report grounding tasks.

## 5 Discussion

ReXGroundingCT is the first publicly available manually annotated dataset to link free text radiology findings with precise pixel-level segmentations in 3D chest CT scans. Unlike prior datasets, which rely on categorical labels or structured annotations, ReXGroundingCT captures the full variability of clinical language through sentence-level grounding to volumetric imaging.

ReXGroundingCT supports two core tasks central to advancing multimodal medical AI: (1) *finding grounding*, which involves localizing the spatial extent of a specific free-text finding in a 3D CT scan, and (2) *grounded report generation*, where a model must generate descriptive radiology reports with spatial references aligned to pixel-level segmentations [6]. These tasks move beyond traditional classification or bounding-box localization by requiring fine-grained spatial reasoning and natural language understanding within volumetric data.

Linking free-text radiology reports to precise 3D segmentations also has direct clinical relevance. Such tools could reduce the time and effort required for radiologists and clinicians to correlate narrative reports with imaging findings, facilitate clearer communication with referring physicians, and potentially reduce unnecessary consultations [14]. For patients, visual context directly linked to report language may improve comprehension and engagement with their health information [16]. Radiology trainees stand to benefit from systems that visually connect descriptive findings to anatomical regions, supporting the development of spatial reasoning skills essential for diagnostic accuracy [15].

Although several chest CT datasets have been developed to support disease classification [3] and lesion segmentation tasks [5, 4, 8], they typically rely on structured metadata or limited label taxonomies. These constraints limit their ability to support open-ended language inputs or nuanced radiological descriptions. More similar to our work, PadChest-GR introduced sentence-level grounding to address this gap but is limited to chest X-rays and bounding-box annotations [9]. OminiAbnorm-CT [24] introduces a large-scale dataset for grounding and describing abnormalities in multi-plane CT across the whole body, but is limited to 2D key slices from Radiopaedia and requires a paid license for use in machine learning applications, which restricts accessibility. RadGenome-Chest CT [23] provides region-grounded supervision using automated organ-level segmentations and sentence-region matching for chest CT, but does not focus on disease-level

findings. RadGPT [7] introduces AbdomenAtlas 3.0, a large-scale abdominal CT dataset where all structured and narrative radiology reports are automatically generated from per-voxel tumor and organ segmentations using a deterministic pipeline and large language models. MedTrinity-25M [22] provides over 25 million multigranular image–ROI–description triplets across ten imaging modalities, generated automatically using expert models and retrieval-augmented multimodal language models. ReXGroundingCT advances this line of work by providing expert-monitored, disease-level sentence grounding in volumetric chest CT with dense, pixel-level segmentations that are manually annotated.

## 6 Conclusion

ReXGroundingCT introduces the first manually annotated publicly available dataset that links free-text radiology findings to expert-monitored 3D segmentations in chest CT scans. By capturing the full expressiveness of clinical language and grounding it in volumetric space, the dataset addresses a critical gap in the development of grounded radiology report generation systems. Through a structured pipeline involving standardized report rewriting, high-fidelity finding extraction and categorization, and quality-assured pixel-level annotation, ReXGroundingCT enables new research directions in sentence-level grounding. We hope this resource will serve as a foundation for advancing explainable and anatomically grounded AI systems in medical imaging.

## 7 Acknowledgement

This research was supported by a grant of the Boston-Korea Innovative Research Project through the Korea Health Industry Development Institute (KHIDI), funded by the Ministry of Health & Welfare, Republic of Korea (Grant number: RS-2024-00403047).

We also thank Dr. Abdulrhman Aljouie for facilitating the international collaboration with King Abdullah Specialized Children’s Hospital and King Abdulaziz Medical City in Riyadh, Saudi Arabia.

## References

- [1] Gwénolé Abgrall, Andre L Holder, Zaineb Chelly Dagdia, Karine Zeitouni, and Xavier Monnet. Should ai models be explainable to clinicians? *Critical Care*, 28(1):301, 2024.
- [2] Josh Achiam, Steven Adler, Sandhini Agarwal, Lama Ahmad, Ilge Akkaya, Florencia Leoni Aleman, Diogo Almeida, Janko Altschmidt, Sam Altman, Shyamal Anadkat, et al. Gpt-4 technical report. *arXiv preprint arXiv:2303.08774*, 2023.

- [3] Parnian Afshar, Shahin Heidarian, Nastaran Enshaei, Farnoosh Naderkhani, Moezedin Javad Rafiee, Anastasia Oikonomou, Faranak Babaki Fard, Kaveh Samimi, Konstantinos N Plataniotis, and Arash Mohammadi. Covid-ct-md, covid-19 computed tomography scan dataset applicable in machine learning and deep learning. *Scientific Data*, 8(1):121, 2021.
- [4] Michela Antonelli, Annika Reinke, Spyridon Bakas, Keyvan Farahani, Annette Kopp-Schneider, Bennett A Landman, Geert Litjens, Bjoern Menze, Olaf Ronneberger, Ronald M Summers, et al. The medical segmentation decathlon. *Nature communications*, 13(1):4128, 2022.
- [5] Samuel G Armato III, Geoffrey McLennan, Luc Bidaut, Michael F McNitt-Gray, Charles R Meyer, Anthony P Reeves, Binsheng Zhao, Denise R Aberle, Claudia I Henschke, Eric A Hoffman, et al. The lung image database consortium (lidc) and image database resource initiative (idri): a completed reference database of lung nodules on ct scans. *Medical physics*, 38(2):915–931, 2011.
- [6] Shruthi Bannur, Kenza Bouzid, Daniel C Castro, Anton Schwaighofer, Anja Thieme, Sam Bond-Taylor, Maximilian Ilse, Fernando Pérez-García, Valentina Salvatelli, Harshita Sharma, et al. Maira-2: Grounded radiology report generation. *arXiv preprint arXiv:2406.04449*, 2024.
- [7] Pedro RAS Bassi, Mehmet Can Yavuz, Kang Wang, Xiaoxi Chen, Wenxuan Li, Sergio Decherchi, Andrea Cavalli, Yang Yang, Alan Yuille, and Zongwei Zhou. Radgpt: Constructing 3d image-text tumor datasets. *arXiv preprint arXiv:2501.04678*, 2025.
- [8] Patrick Bilic, Patrick Christ, Hongwei Bran Li, Eugene Vorontsov, Avi Ben-Cohen, Georgios Kaissis, Adi Szeskin, Colin Jacobs, Gabriel Efrain Humpire Mamani, Gabriel Chartrand, et al. The liver tumor segmentation benchmark (lits). *Medical image analysis*, 84:102680, 2023.
- [9] Daniel Coelho de Castro, Aurelia Bustos, Shruthi Bannur, Stephanie L Hyland, Kenza Bouzid, Maria Teodora Wetscherek, Maria Dolores Sánchez-Valverde, Lara Jaques-Pérez, Lourdes Pérez-Rodríguez, Kenji Takeda, et al. Padchest-gr: A bilingual chest x-ray dataset for grounded radiology report generation. *NEJM AI*, 2(7):AIdbp2401120, 2025.
- [10] MJJ de Grauw, E Th Scholten, Ewoud J Smit, Matthieu JCM Rutten, M Prokop, B van Ginneken, and Alessa Hering. The uls23 challenge: A baseline model and benchmark dataset for 3d universal lesion segmentation in computed tomography. *Medical Image Analysis*, 102:103525, 2025.
- [11] L John Fahrner, Emma Chen, Eric Topol, and Pranav Rajpurkar. The generative era of medical ai. *Cell*, 188(14):3648–3660, 2025.
- [12] Feng Gao, Minhao Hu, Min-Er Zhong, Shixiang Feng, Xuwei Tian, Xiaochun Meng, Zeping Huang, Minyi Lv, Tao Song, Xiaofan Zhang, et al. Segmentation only uses sparse annotations: Unified weakly and semi-supervised learning in medical images. *Medical Image Analysis*, 80:102515, 2022.
- [13] Ibrahim Ethem Hamamci, Sezgin Er, Chenyu Wang, Furkan Almas, Ayse Gulnihan Simsek, Seval Nil Esirgun, Irem Doga, Omer Faruk Durugol, Weicheng Dai, Murong Xu, et al. Developing generalist foundation models from a multimodal dataset for 3d computed tomography. *arXiv preprint arXiv:2403.17834*, 2024.
- [14] Veena R Iyer, Peter F Hahn, Lawrence S Blaszkowsky, Sarah P Thayer, Elkan F Halpern, and Mukesh G Harisinghani. Added value of selected images embedded into radiology reports to referring clinicians. *Journal of the American College of Radiology*, 7(3):205–210, 2010.
- [15] Jort Karstens, Lucas Boer, Thomas Maal, and Dylan Henssen. The possible impact of segmenting radiological images on students’ spatial abilities. *Discover Education*, 3(1):83, 2024.
- [16] Luyang Luo, Jenanan Vairavamurthy, Xiaoman Zhang, Abhinav Kumar, Ramon R Ter-Oganesyan, Stuart T Schroff, Dan Shilo, Rydhwana Hossain, Mike Moritz, and Pranav Rajpurkar. Rexplain: Translating radiology into patient-friendly video reports. In *AAAI Bridge Program on AI for Medicine and Healthcare*, pages 109–120. PMLR, 2025.
- [17] Vishwanatha M Rao, Michael Hla, Michael Moor, Subathra Adithan, Stephen Kwak, Eric J Topol, and Pranav Rajpurkar. Multimodal generative ai for medical image interpretation. *Nature*, 639(8056):888–896, 2025.
- [18] Zahra Sadeghi, Roohallah Alizadehsani, Mehmet Akif Cifci, Samina Kausar, Rizwan Rehman, Priyakshi Mahanta, Pranjal Kumar Bora, Ammar Almasri, Rami S Alkhawaldeh, Sadiq Hussain, et al. A review of explainable artificial intelligence in healthcare. *Computers and Electrical Engineering*, 118:109370, 2024.
- [19] Christina Silcox, Eyal Zimlichmann, Katie Huber, Neil Rowen, Robert Saunders, Mark McClellan, Charles N Kahn III, Claudia A Salzberg, and David W Bates. The potential for artificial intelligence to transform healthcare: perspectives from international health leaders. *NPJ Digital Medicine*, 7(1):88, 2024.

- [20] Jakob Wasserthal, Hanns-Christian Breit, Manfred T Meyer, Maurice Pradella, Daniel Hinck, Alexander W Sauter, Tobias Heye, Daniel T Boll, Joshy Cyriac, Shan Yang, et al. Totalsegmentator: robust segmentation of 104 anatomic structures in ct images. *Radiology: Artificial Intelligence*, 5(5):e230024, 2023.
- [21] Adrian Wolny, Qin Yu, Constantin Pape, and Anna Kreshuk. Sparse object-level supervision for instance segmentation with pixel embeddings. In *Proceedings of the IEEE/CVF Conference on Computer Vision and Pattern Recognition*, pages 4402–4411, 2022.
- [22] Yunfei Xie, Ce Zhou, Lang Gao, Juncheng Wu, Xi-anhang Li, Hong-Yu Zhou, Sheng Liu, Lei Xing, James Zou, Cihang Xie, et al. Medtrinity-25m: A large-scale multimodal dataset with multigranular annotations for medicine. In *The Thirteenth International Conference on Learning Representations*.
- [23] Xiaoman Zhang, Chaoyi Wu, Ziheng Zhao, Ji-ayu Lei, Ya Zhang, Yanfeng Wang, and Weidi Xie. Radgenome-chest ct: A grounded vision-language dataset for chest ct analysis. *arXiv preprint arXiv:2404.16754*, 2024.
- [24] Ziheng Zhao, Lisong Dai, Ya Zhang, Yanfeng Wang, and Weidi Xie. Rethinking whole-body ct image interpretation: An abnormality-centric approach. *arXiv preprint arXiv:2506.03238*, 2025.

## A Number of Entities for Each Finding Category

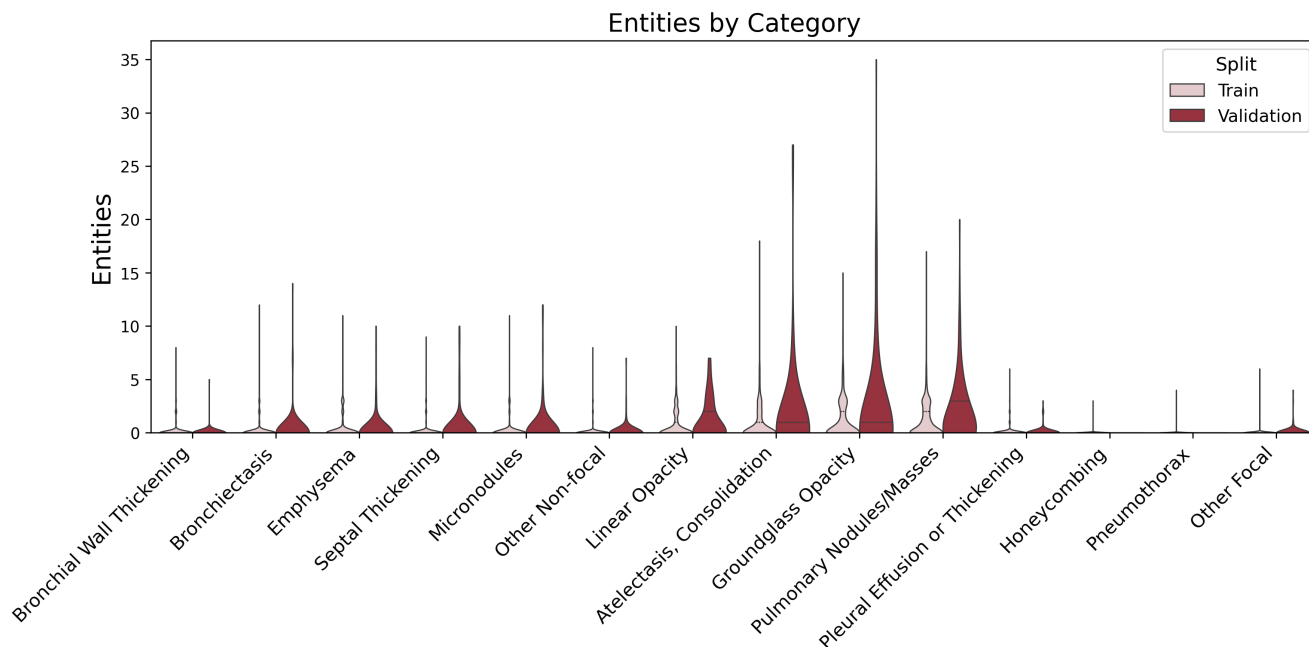


Figure A.1: Distribution of segmented entities per finding category. Validation distributions show greater mass at higher entity counts (e.g.,  $>3$ ), reflecting the exhaustive labeling protocol in which all visible instances were segmented. In contrast, the training set was limited to at most three representative instances per finding to reduce annotation workload.

## B Relative size of Finding Categories

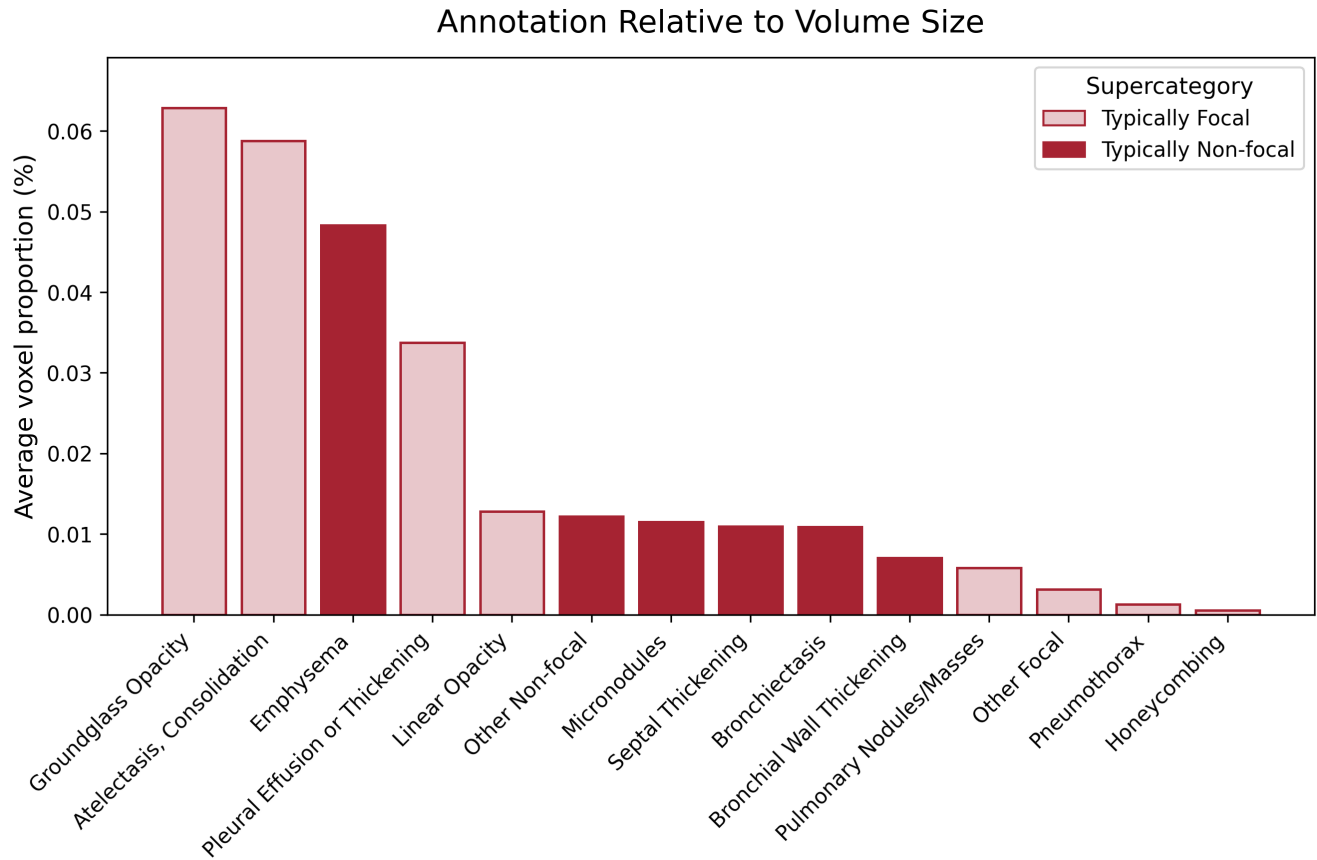
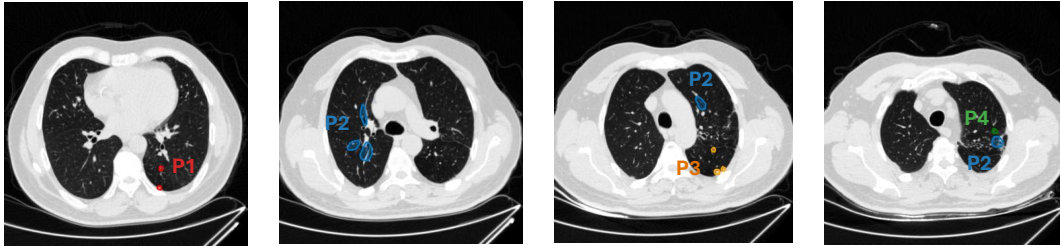
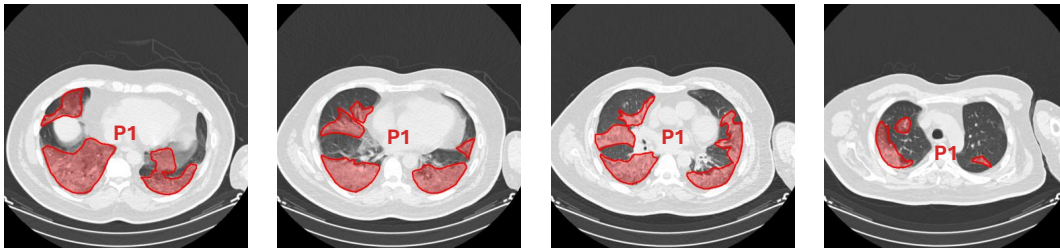


Figure B.1: Average annotation ground truth size with respect to volume size per finding category.

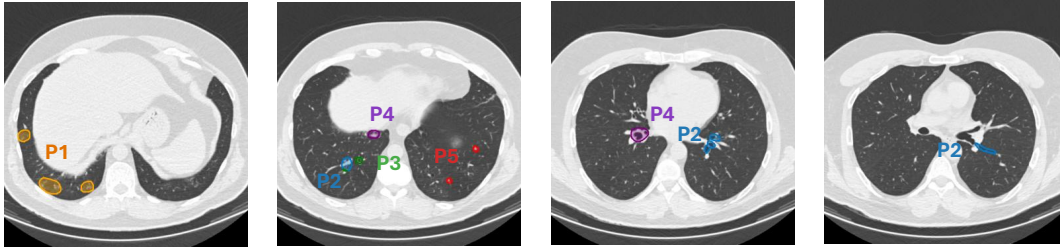
## C Examples from the Dataset



- P1: Nonspecific nodular densities in the superior segment of the left lower lobe
- P2: Mild traction bronchiectasis in the apical segments of the upper lobes of both lungs
- P3: Nonspecific subcentimeter nodules in both lungs, more prominent on the left
- P4: Nonspecific nodular densities in the apical segment of the left upper lobe



- P1: Diffuse ground-glass opacities in both lungs



- P1: Peribronchial reticulonodular densities with faint borders in the lower lobes
- P2: Bronchiectasis in both lower lobes
- P3: Minimal thickening of the bronchial walls
- P4: Bronchiectasis most prominently at the central level of the right lower lobe
- P5: Subcentimeter nonspecific nodules in both lungs

Figure C.1: Additional Examples from the dataset.

## D Hierarchical Tree Finding Categories

- 1) Typically non-focal lung/airway/pleural abnormalities
  - 1a) Bronchial wall thickening
  - 1b) Bronchiectasis
  - 1c) Emphysema (including Centrilobular, Paraseptal, Bullous)
  - 1d) Septal thickening (including Interlobular, Reticulation)
  - 1e) Micronodules (including Centrilobular, Tree-in-bud, Perilymphatic)
  - 1f) Other
- 2) Typically focal lung/airway/pleural opacities
  - 2a) Linear (including subsegmental atelectasis, scarring, fibrosis)
  - 2b) Atelectasis, consolidation
  - 2c) Groundglass opacity
  - 2d) Pulmonary nodules/masses
  - 2e) Pleural effusion or thickening
  - 2f) Honeycombing
  - 2g) Pneumothorax
  - 2h) Other
- 3) Non-pulmonary lesions
  - 3a) Lymphadenopathy lesions
  - 3b) Liver lesions
  - 3c) Gallbladder lesions
  - 3d) Renal/kidneys, collecting system, and ureters lesions
  - 3e) Spleen lesions
  - 3f) Adrenal lesions
  - 3g) Pancreas lesions
  - 3h) Thyroid lesions
  - 3i) Skin/subcutaneous lesions
  - 3j) Bone/Osseous structures lesions
  - 3k) Other lesions
- 4) Bones (non-lesion)
  - 4a) Fractures
  - 4b) Degenerative joint disease, degenerative disc disease, arthritis
  - 4c) Spinal curvature abnormalities: kyphosis, scoliosis
  - 4d) Other
- 5) Stones/organ calcifications (non-lesion)
  - 5a) Nephroliths, choleliths
  - 5b) Granulomas
  - 5c) Other
- 6) Hollow viscera abnormalities
  - 6a) Hiatus hernia
  - 6b) Wall thickening
  - 6c) Dilated
  - 6d) Diverticulum (including diverticulosis)
  - 6e) Other
- 7) Skin/subcutaneous (non-lesion)
  - 7a) Skin thickening
  - 7b) Stranding
  - 7c) Abdominal wall hernia: ventral, umbilical, inguinal
  - 7d) Gynecomastia
  - 7e) Other
- 8) Cardiovascular
  - 8a) Atherosclerosis (including coronary, non-coronary)
  - 8b) Vessel aneurysm, ectasia, enlargement
  - 8c) Vessel occlusion or stenosis
  - 8d) Cardiac chamber enlargement
  - 8e) Valvular calcification

- └─ 8f) Pericardial effusion
- └─ 8g) Other
- 9) Body composition
  - └─ 9a) Visceral fat
  - └─ 9b) Superficial subcutaneous fat
  - └─ 9c) Skeletal muscle
  - └─ 9d) Osteoporosis
  - └─ 9e) Hepatic steatosis
  - └─ 9f) Other
- 10) Diffuse/whole organ
  - └─ 10a) Organomegaly (including splenomegaly, multinodular goiter, thyromegaly, lung hyperinflation)
  - └─ 10b) Atrophy
  - └─ 10c) Other
- 11) Device
  - └─ 11a) Elongated (including catheter, pacemaker/defibrillator, spinal stimulator)
  - └─ 11b) Surgical clips
  - └─ 11c) Other
- 12) Other